

Carnicom Institute Research

2008

Acknowledgements

Mission Statement:

Carnicom Institute is a non-profit organization working solely for the benefit of humanity. Our goal is to provide the public with beneficial and responsible information through scientific, educational, environmental, and health research for the public welfare. The Institute has devoted significant effort to the important issues of geoengineering and bioengineering.

Disclaimer:

The Carnicom Institute is a non-profit health and environmental educational and research organization serving the public welfare. CI is not a clinic and does not perform any medical diagnosis, medical treatment, or prescription of therapy. We do not advocate any proprietary products, protocols, or therapies. All studies conducted by the Institute are for research purposes only. Our purpose is to provide information and education to the public.

License:

Carnicom Institute by is licensed under a Creative Commons Attribution-NonCommercial-NoDerivatives 4.0 International License. <https://creativecommons.org/licenses/by-nc-nd/4.0>

Table of Contents

Jan	1
MORGELLONS: AGENTS OF INFECTION	1
MORGELLONS: A FOURTH MATCH	4
AND NOW OUR CHILDREN	9
MORGELLONS: 5th, 6th & 7th MATCH	13
MORGELLONS... A Natural Medicine Approach	22
Mar	28
MORGELLONS: PATHOGENS & THE GENERAL POPULATION	28
"MORGELLONS:" THE WINE - PEROXIDE TEST	37
Morgellons - Introductory Remarks with Dr. Gwen Scott	41
Apr	42
Morgellons - 2nd Session - with Dr. Gwen Scott	42
AEROSOL ANOMALIES	43
Jun	49
Instructions for Boosting Your Microscope's Power to Examine Your Own Samples	49
Jul	60
CULTURE BREAKTHROUGH(?)	60
Aug	71
CULTURE WORK IS CONFIRMED	71
MORGELLONS: GROWTH CAPTURED	79

Jan

MORGELLONS: AGENTS OF INFECTION

Jan 1, 2008

**MORGELLONS:
AGENTS OF INFECTION****Clifford E Carnicom****Jan 01 2008**

Several important papers have recently been published that demonstrate the potential for a public health crisis. There is a need, which has been called for, to immediately identify at least two structural forms which have been repeatedly observed and reported on. These forms are crossing airborne and biological lines and they have now been observed in airborne, skin, dental and blood samples.

I am not aware of any public or professional comment or dialogue on the reports that have been filed in recent weeks, or of any response to the originating August 2006 paper entitled [Morgellons : First Observations](#).

I have not been contacted by the Centers for Disease Control for any specifics on the reports. I have not been contacted by the U.S. Environmental Protection Agency for additional information, even though one of the samples under investigation is the very same airborne sample that they refused to identify several years ago. These agencies have failed in serving the public welfare for many years now. No public or private health official or professional, to my knowledge, has provided any significant feedback on the many questions that have been raised with the similarity of these samples. The ruse of foisting an assessment of "delusion" in direct contradiction to physical sampling has run its course and is no longer operable. The situation remains completely and totally inexcusable at all levels, public and private.

As a consequence, I am forced to attempt identification as best as is possible with the limited resources that I have. This is an incomplete process and it is unlikely to ever be resolved with these limitations. I will provide what I can to date; research continues as time provides. The public will eventually be required to force the call to completion.

I am not offering any medical position, advice or diagnosis in the presentation of this information, nor will I. I have no medical expertise and I claim none. I will provide observations, analysis and assessment from the standpoint of an independent researcher to the most capable fashion that I can. The appeal for public and professional involvement remains standing as it has for many years now.

There are those that claim exotic technologies (nanotechnology, artificial intelligence, etc.) are at work in the Morgellon's issue. This may very well be true and is not unexpected in any way. However, there are some basic matters that need to be attended to. With the observations and analysis that have surfaced from this researcher of late, there is a hierarchy of investigation that needs to be pursued. It is:

1 Conventional scientific expertise should be applied to the problem of identification of these two forms. This includes, but is not limited to, the professions of biology, microbiology, chemistry, pathology, health and medicine.

2. Modified or unconventional biological forms or interaction are then reasonable to consider.

3. Artificial, exotic and unfamiliar technologies could be explored for any relationship to unexplainable events or circumstances.

Each of these must be dealt with in due order. If any individual is going to jump to number three on this list, they are going to have offer the proof in a visible, direct or comprehensive manner; even nanotechnology is quite visible with the right equipment and will require demonstration if it is involved. It will also need to be explained how numbers one and two have failed in the consideration. It is not wise to concentrate on what we cannot see or do not have access to until we have dealt with what we can see and what we do have access to. In addition, the profit motive must be excluded from the pursuit of truth on this matter.

As such, I will commence with item one of this list and I shall exhaust it to the maximum degree possible before moving on. It would seem to me that there is already “plenty of explaining” to do on level one with the information that is currently available through direct observation alone.

Now for more specifics. There are two forms that require immediate identification as to their physical nature, function and purpose. The first of these is a sub-micron repeating filament that is enclosed within a larger bounding filament. The sub-micron filaments can only be seen with fairly advanced microscopy; the bounding filament is visible to the naked eye in many cases. The second form is a circular, spherical or oblate structure that also is measuring at the micron to sub-micron level. The best estimate for the size of this structure is currently on the order of 0.5 to 0.7 microns. Size, as will be seen, is a very important factor in any identification process. If and when level one has been applied to identify these structural forms and when it has convincingly failed it will be appropriate to advance to levels two and three.

A few general principles will be helpful to set the stage for the discussion to follow:

Agents of infectious disease can include the following floral forms: bacteria, fungi, viruses, parasites, prions, rickettsiae, and chlamydiae¹. These will each be examined individually with respect to the two structural forms. The discussion will eventually focus on the blood samples, as they are becoming especially problematic to explain or account for. The blood itself is generally to be regarded as a “sterile environment”², and pathogens of any kind in the blood are not to be expected and represent a very serious health concern. No non-pathogenic forms of the flora listed above are to be found in the blood.³ Therefore, if we do find any of the forms above in the blood, they are to be regarded as pathogenic and consequently of serious health concern.

Let us begin with the filament form, as the discussion is more limited based upon what can be observed with available equipment. What is known is this: The visible form is that of a “bounding filament”. The diameter of the bounding filament generally ranges from 20-40 microns in thickness. The bounding filament has been identified in the airborne, skin and dental samples; it has not been demonstrated absolutely within the blood samples. A filamentous form has been observed in the blood sample from the Morgellon’s individual ([Blood Testing, Laser, Morgellons & Fungus\(?\)](#)), but only to a general level and not at the magnification level that will eventually be required. Within the airborne, dental and skin fiber samples, a distinguishing feature is an “internal network” of filaments that are sub-micron in diameter. The best measurement attained thus far is on the order of 0.7 microns (a human hair is approximately 60-100 microns thick).

A first approach is to ask whether or not the bounding or the primary filament forms can conceivably be any of the floral forms listed above. If not, we can reasonably elevate the investigation to stage two of the hierarchy. We can likely eliminate viruses in this consideration because they are not generally visible

with the available equipment. Viruses are generally on the order of .01 to .10 microns; and this is beneath the range of current consideration. The largest virus identified, Mimivirus virion, measures 0.4 microns; and although this is in range of the the equipment available, there is structually no similiarity.⁴ The size of the bounding filament realistically further eliminates the virus consideration; we will eventually have to consider the joint existence of the bounding filament as well as the internal filament network during the identification process.

Parasites are of eukaryotic and of worm form. The size criteria alone is generally going to eliminate any know parasitic forms. Eukaryotic forms, such as protozoa, are on the order of 10 microns to 100 microns in size. If we were dealing with the bounding filament from alone, we might morel seriously examine known parasitic forms. However, the internal sub-micron filament network excludes the eukaryotic cell forms based upon size alone. In addition, there has yet to be any identification of internal cell organelles or structure characteristic of eukaryotic form. At this point, we can therefore not attach any known parasitic identity to the bounding-internal network filamentous form.

THIS PAGE IS IN PROGRESS;

THE WORK ON THIS PAPER WILL CONTINUE AS TIME AND CIRCUMSTANCES PERMIT.

References:

1. C. Porth, Pathophysiology, Concepts of Altered Health States, 6th Edition (Lippincott, 2002, p 310)
2. W. Strohl, Microbiology (Lippincott, 2001, p7)
3. Porth, 310.
4. Mimivirus (largest known virus), <http://www.rkm.com.au/VIRUS/MIMIVIRUS/index.html>

MORGELLONS: A FOURTH MATCH

Jan 1, 2008

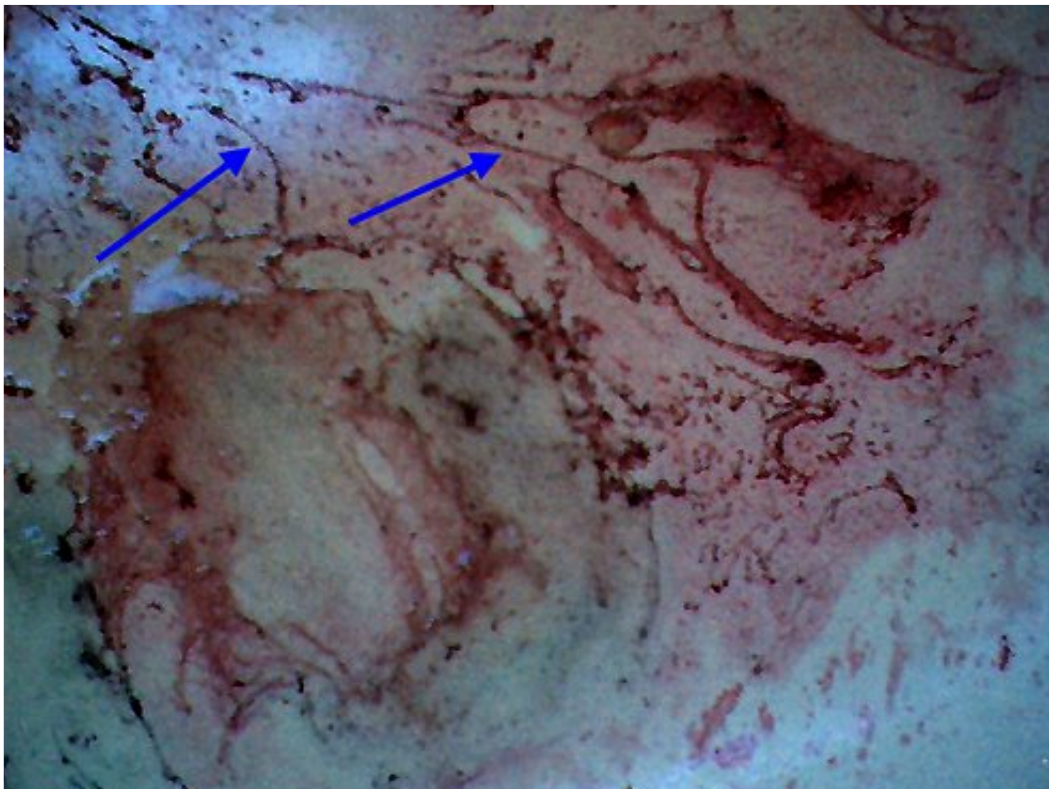
**MORGELLONS:
A FOURTH MATCH
Clifford E Carnicom
Jan 01 2008**

An individual with Morgellons symptoms has recently expelled a massive volume of fibrous material from the gums of the mouth. This individual is the same as that reported in the paper [Morgellons Morphology Confirmed](#). The experience up to and including the event was extremely painful to the subject.

The nature of the fibers, upon very high magnification, reveal themselves to be identical in size, structure and form to the skin fibers that are documented in detail on the paper referenced above.

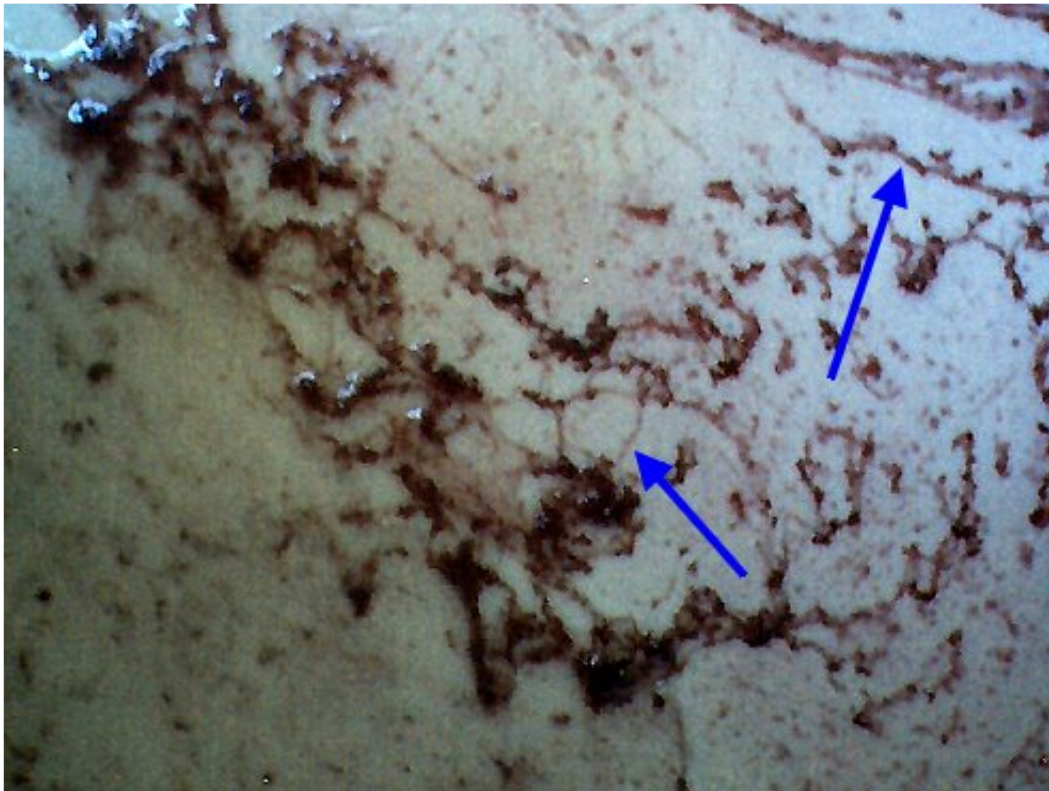
This now brings to four the number of samples from entirely different mediums and environments that are showing similar to identical morphology. These include the airborne fiber as refused by the U.S. Environmental Protection Agency, the skin fibers as manifest with the Morgellon's individual, the blood sample of the Morgellon's individual and the dental sample from this latest event.

The fact that such widespread diversity in environment and conditions is producing these samples of remarkable similarity demonstrates the magnitude of the Morgellons and aerosol issues. It remains an open question as to what level of reporting is required to motivate the general citizenry to act upon these topics.




A small portion of the original dental material as expelled from the gums of the individual with Morgellons symptoms.

Arrows point to instances of what APPEAR to be individual filaments (actually composed of innumerable sub-filaments at the micron to sub-micron level).
 Sample expelled into kitchen sink; red coloration results from wine which was found to be useful as an extraction fluid.
 Extreme dental pain encountered by the individual prior to the expulsion process.
 More moderate, but still severe, pain continued during the expulsion process which occurred over several days.
 Magnification approx. 5x.



Another segment of the dental filament sample expelled from the gums of the individual.
 Arrows point to additional instances of isolated filaments.
 Darker and more extensive masses are comprised of filament masses.
 Magnification approx. 10x.



The dental filament sample at extreme magnification.

What is enclosed between the black boundaries is what appears to the eye to be a single filament. Internal network of micron to sub-micron filaments becomes evident.

Notice that this dental sample is remarkably similar in form, size & shape to airborne, skin & blood samples

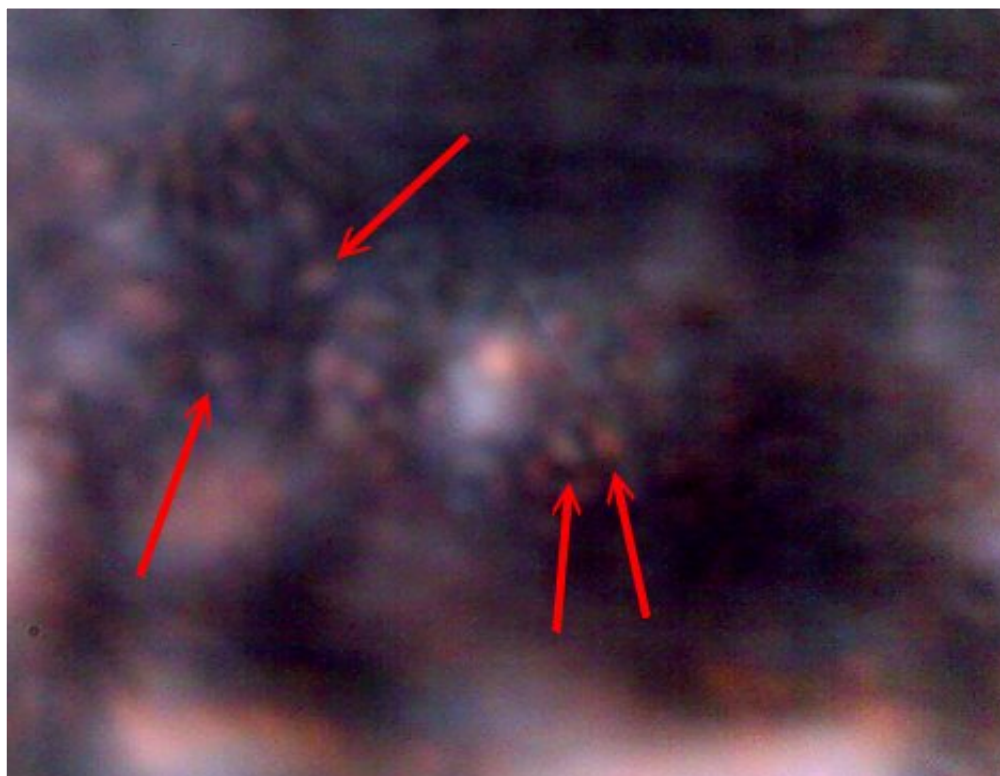
previously reported on [Morgellons: Airborne, Skin & Blood – A Match](#)

Blue arrows point to individual sub-micron fibers within the enclosing filament.

Black bars point to general exterior boundary of enclosing filament.

Notice interior circular/spherical structures within (red arrows) as also previously reported on other medium samples.

Magnification approx. 7000x.



Large internal network of sub-micron structures within dental filament sample that have been repeatedly observed across a variety of medium samples (airborne, skin, blood and dental). Please refer to additional reports that have recently been published.

Red arrows point to individual instances.

One of the two basic forms (sub-micron filament & sub-micron circular/spherical entity) that requires identification. Magnification approx. 7000x.

Additional notes:

Readers may also wish to familiarize themselves with the report entitled, [Morgellons: Airborne, Skin & Blood – A Match](#) on this site. It may be beneficial to be aware of the additional reports : [Morgellons : First Observations](#), [Morgellons Morphology Confirmed](#) and [Blood Testing](#). It may also be of interest to recall an earlier report filed in December of 2003 entitled, [Unusual Medical Finding](#). There may or may not be a relationship between the December 2003 event and the current affliction of this report. The latter report has historically received some attention from those that chose to attempt to discredit the aerosol and Morgellons issues. It was often stated that the subject(i.e., this researcher) self-inflicted unnecessary pain during that fiber removal process. It is fair to say that that the amount of pain incurred in the pre-emptive 2003 event was quite minor relative to what the subject of this current report endured. People may wish to keep that fact in mind as the magnitude of the Morgellon's issue is more fully understood.

There are some additional aspects to the December 2003 event involving laser phototropic response and persistence of condition that may eventually become relevant and require further elaboration.

The identical morphology between the dental filaments of this report and the skin filaments of recent report appears to remove any consideration of actinomyces consideration in this event. Actinomyces remains one of many considerations of the 2003 event.

Readers may also wish to begin recalling a paper entitled [Extraordinary Biological Observations](#), dated May 02, 2004.

AND NOW OUR CHILDREN

Jan 11, 2008

AND NOW OUR CHILDREN**Clifford E Carnicom****Jan 11 2008**

Observation of blood samples from numerous individuals has intensified over the past couple of weeks. A more detailed analysis of the anomalies first reported in the paper [Blood Testing](#) has taken place and it is continuing. In the interest of full and rapid disclosure of research underway, this paper reports the following:

1. A preliminary assessment as to the nature of one of two primary structural forms within the blood anomalies has been reached. This effort has been necessary due to the failures of the Centers for Disease Control, the U.S. Environmental Protection Agency and the professional medical communities at large. The assessment is not final by any means, but due to its importance as an avenue for immediate investigation it is to be released. I am not offering or providing any medical advice or opinion in this report. I have no medical expertise and I claim none. Information provided here comes strictly from the position of analysis and observation. The assessment is that Chlamydiae or Chlamydiae-like organisms should be considered as a leading candidate for investigation in the Morgellon's pursuit as well as in the investigation of the aerosol operations. A more detailed analysis of the rationale behind that assessment will be provided in another paper, [Agents of Infection](#) as time and circumstance permit.
2. The vast majority of all blood samples observed (if not all) are showing various degrees of anomalous form. The degree of damage to cellular integrity and form appears to correspond directly to the number of anomalous structures that are found within any individual sample.
3. The anomalies in a variety of blood samples have transcended the age factor, and they have now also been observed in the same fashion and form within the blood of a nine year old child.

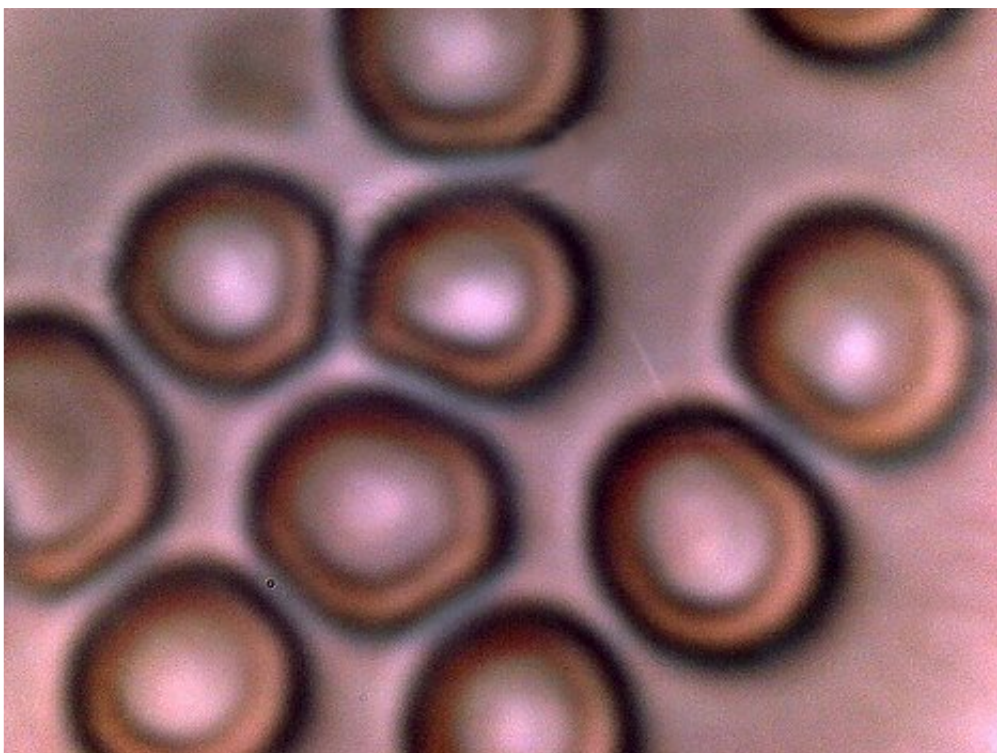
In brief, the method of assessment is as follows:

1. The organism involved must measure on the order of sub-micron, generally on the order of 0.5 to 0.7 microns.
2. The organism is an intra-cellular organism, and can exist within human red blood cells (erythrocytes).
3. The organism is likely to be associated with respiratory conditions and is circulated by aerosol means.
4. The organism is spherical to oblate, but can exist in more than one form (pleomorphic).
5. Gram stain procedures applied to the blood samples should produce a gram-negative result.
6. The same form, at least by inspection and measurement, should in general be present in diverse Morgellon physical samples, the airborne fibers under long term investigation (EPA refused) and the blood of Morgellon individuals. The general population may also demonstrate a marked presence of the pathogen.
7. The illnesses that are associated with the Chlamydiae genus should correlate with increasing and

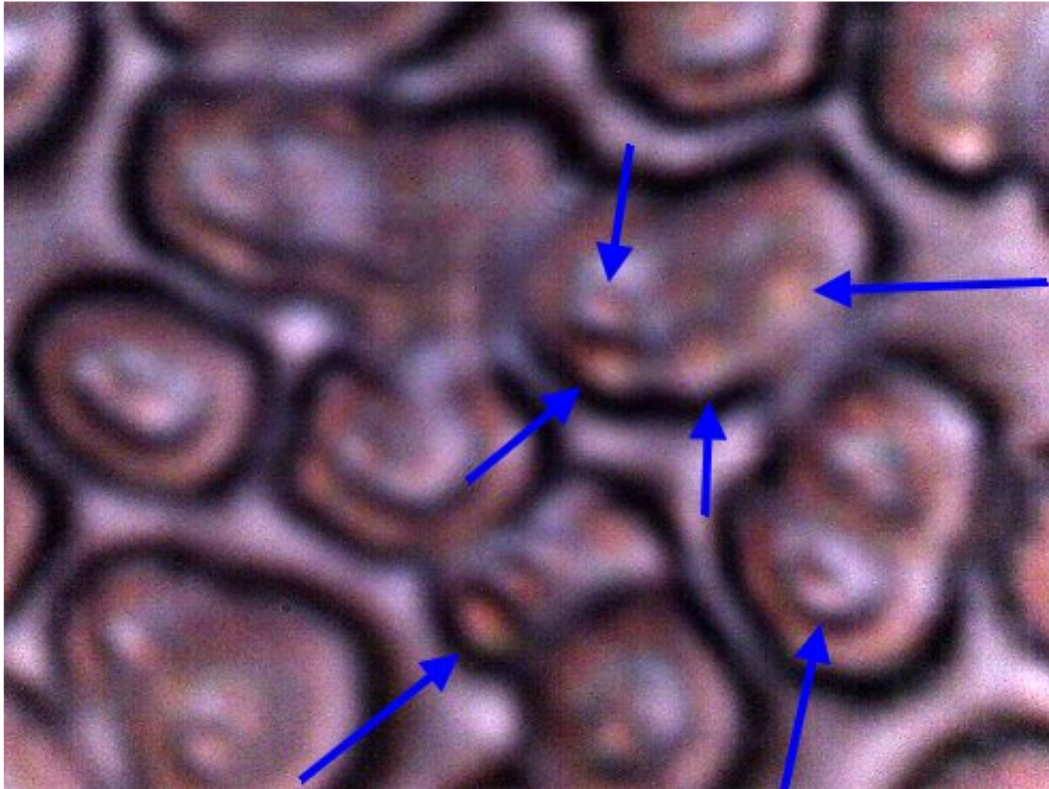
pervasive ailments and diseases.

8. Recorded observations of the pathogen must match the accumulated observations of this researcher.

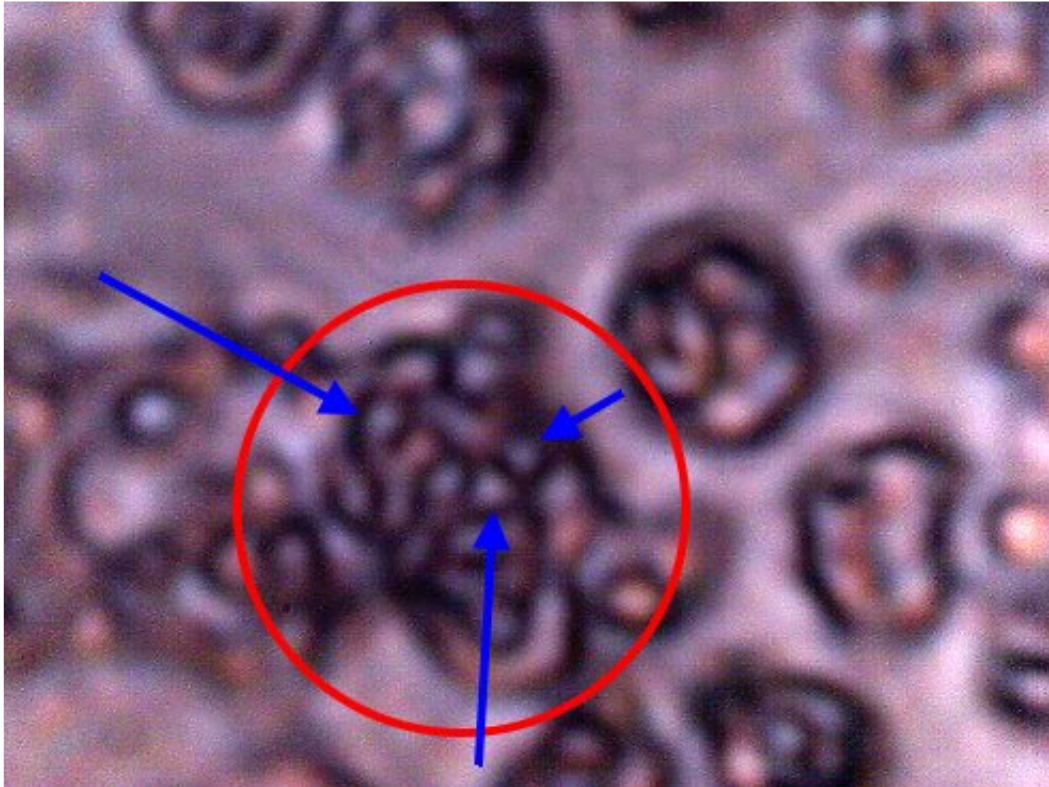
Considerable attention has been given to the consideration of alternative explanations, such as blood platelet imbalances, conventional bacterial and fungal forms; contradictions to one or more of the above conditions occur during those analyses. Although all pathogens remain under consideration a focus on Chlamydia-like groups is in place. The Chlamydiae-like group (with a special interest in Chlamydia pneumoniae) satisfies the above conditions to the degree that is understood. Again, this assessment is not intended to be final, but it is offered as the best assessment by this researcher to date. It is not unexpected that modification of a Chlamydia group could take place (e.g., mycoplasma combinations). In addition, the relationships to the second structural form (sub-micron filament network and bounding filaments) will need to be provided.



One of the more normal appearing regions of red blood cells from a nine-year old child.
Magnification approx. 7000x



Anomalous region of blood cells of nine year old child prior to the gram stain process. Cellular integrity damage is apparent. If cellular variation is extensive in the sample, sub-micron structures are often visible(blue arrows) without any staining process involved. Degree of cellular damage appears to correspond directly to the number of chlamydia-like structures within, in contact with or adjacent to the blood cells. Numerous "double"-erythrocyte forms observed in this sample. Magnification approx. 7000x..



Red blood cell of nine year old child after the gram stain process;
visible examination of slide appears to show the gram negative process as highly dominant.
Area within circle encloses erythrocyte (red blood cell) boundary prior to stain process.
Blood cell structure is damaged during the stain process (expected).
Certain bacterial types or bacterial-like types (blue arrows) remain and are emphasized after the stain process.
The intra-cellular (chylamidia-like) structures measure approx. 0.5 – 1.0 microns in diameter.
Due to morphological variation across various samples observed,
crossovers with mycoplasma forms (also pleomorphic) remain under strong consideration.
Magnification approx. 7000x.

MORGELLONS: 5th, 6th & 7th MATCH

Jan 21, 2008

**MORGELLONS:
5th, 6th & 7th MATCH
Clifford E Carnicom
Jan 21 2008**

There are now seven different samples (6 human, 1 airborne) that are showing the same basic apparent pathogenic forms. The seven sample types are:

- 1. Airborne fiber (The U.S. Environmental Protection Agency refuses to identify this sample.)**
- 2. Skin fibers (subject manifests visible Morgellons symptoms)**
- 3. Blood samples (the vast majority of samples observed, regardless of manifest Morgellons symptoms)**
- 4. A gum-dental fibrous expulsion from an individual that manifests visible Morgellons symptoms)**
- 5. A gum-dental infection sample from an individual that does not outwardly manifest Morgellons symptoms.**
- 6. A gum-dental fibrous sample from an individual that does not outwardly manifest Morgellons symptoms.**
- 7. A saliva sample from an individual that does visibly manifest the Morgellon symptoms.**

I state again that I offer no medical advice or diagnosis of the conditions that are being reported here. I have no medical expertise and I claim none. I am offering a series of observations and analyses from the standpoint of independent research.

The pathogenic forms appear to be demonstrating across all age groups and they are not restricted to subjects that visibly manifest the symptoms of Morgellons. In other words, the pathogenic forms appear to be dispersed through a broad cross-section of the individuals that have offered samples for observation and study. The prevalence and degree of the anomalies do appear to correspond to the visible manifestation of the Morgellons condition. There are three basic forms that continue to repeat(formerly two identified). These are:

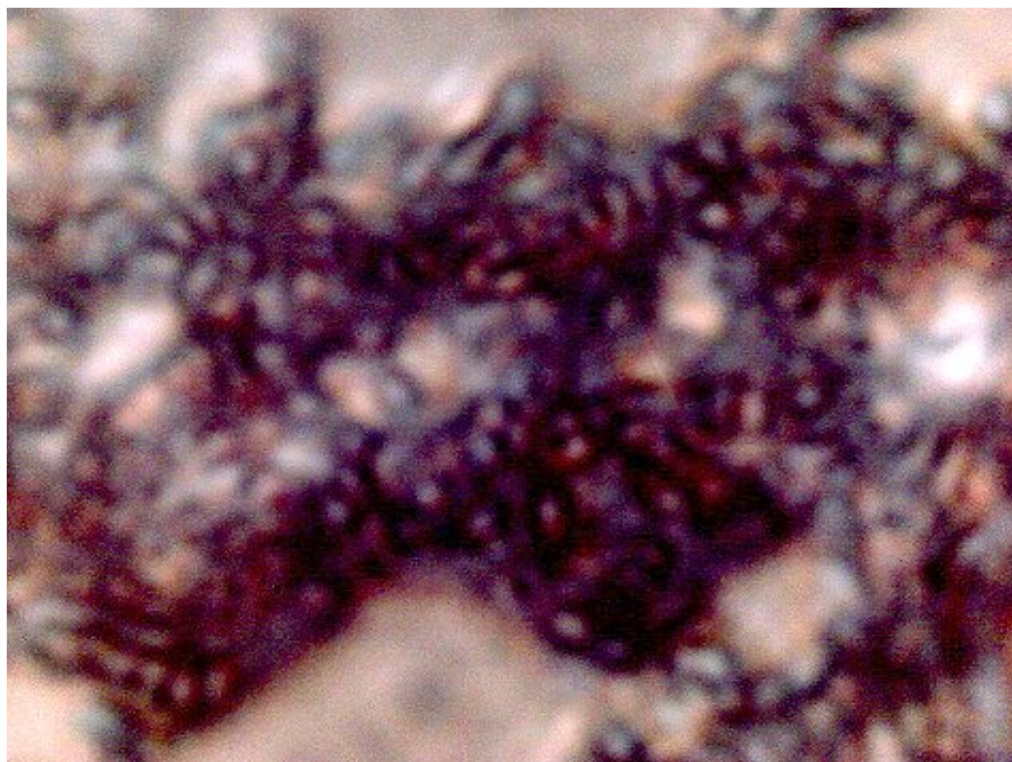
1. The sub-micron spherical or oblate structure referred to repeatedly in recent papers. The best assessment that I can offer to date about the nature of these organisms centers on Chlamydia or Chlamydia-like bacterial organisms, with a special emphasis upon Chlamydia pneumoniae.
2. The filament form is also referenced repeatedly on this site. The filament is composed of two primary aspects: an encasing filament and a sub-micron internal fibrous network. One logical interpretation of this form is that of a delivery mechanism, since it is repeatedly shown to encase the three primary forms that have been observed.
3. The third form repeats itself sufficiently to warrant description. This form appears to be a morph of the previous two; i.e., it shares both the oblate and the filament characteristics mentioned above. The closest match that I can provide to date on this variation centers on certain forms of mycoplasma that have been researched. For the time being, this will be referred to as the *hybrid* form.

The 5th Match:

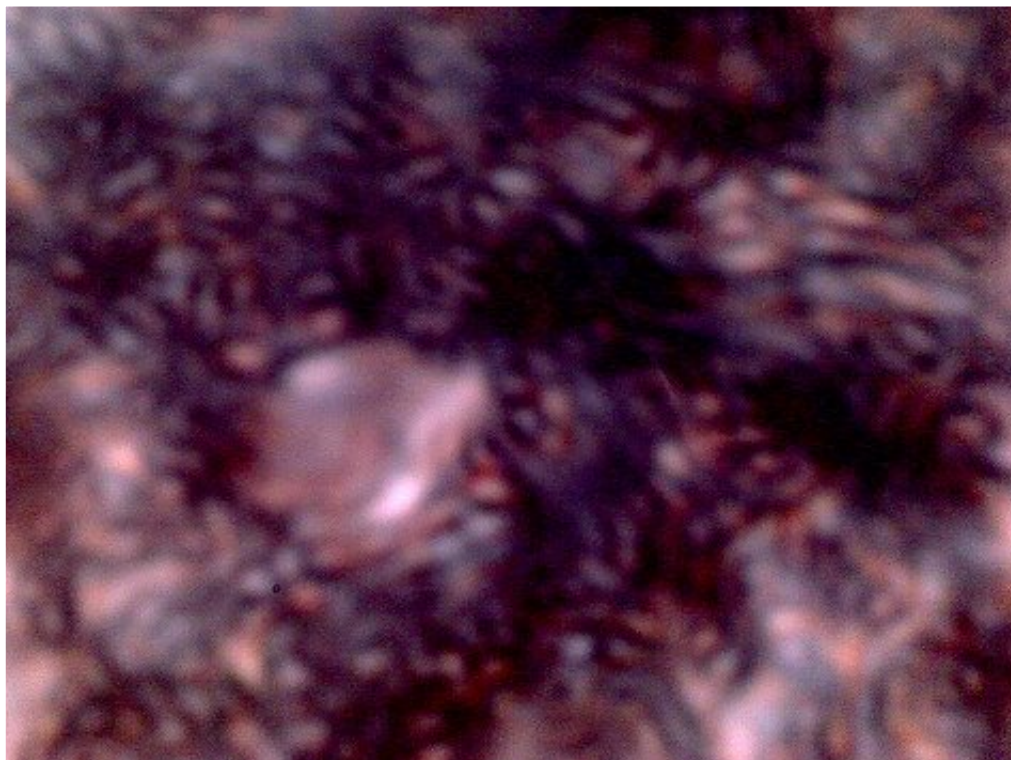
The individual presented here has had a persistent dental-gum condition for several years. This individual does not outwardly manifest the Morgellons condition. The problem was first identified in December of 2003 with the extraction of a fibrous network from within the gum. Subsequent attention to the problem resulted in the disturbance moving from one portion of the gum to another over a period of several months. A phototropic response with the use of laser light was also reported. Eventually the afflicted region became stationary but increasingly difficult to access as the pain resides deep within the gum. Prior to this report, microscopic magnification has not been sufficient to reveal the underlying structures within the affected region. It will be observed that the basic structural form within the gum sample is visibly and metrically identical to that reported in numerous recent reports on this site.

The assessment that is to be made at the end of the fifth match observation set is as follows:

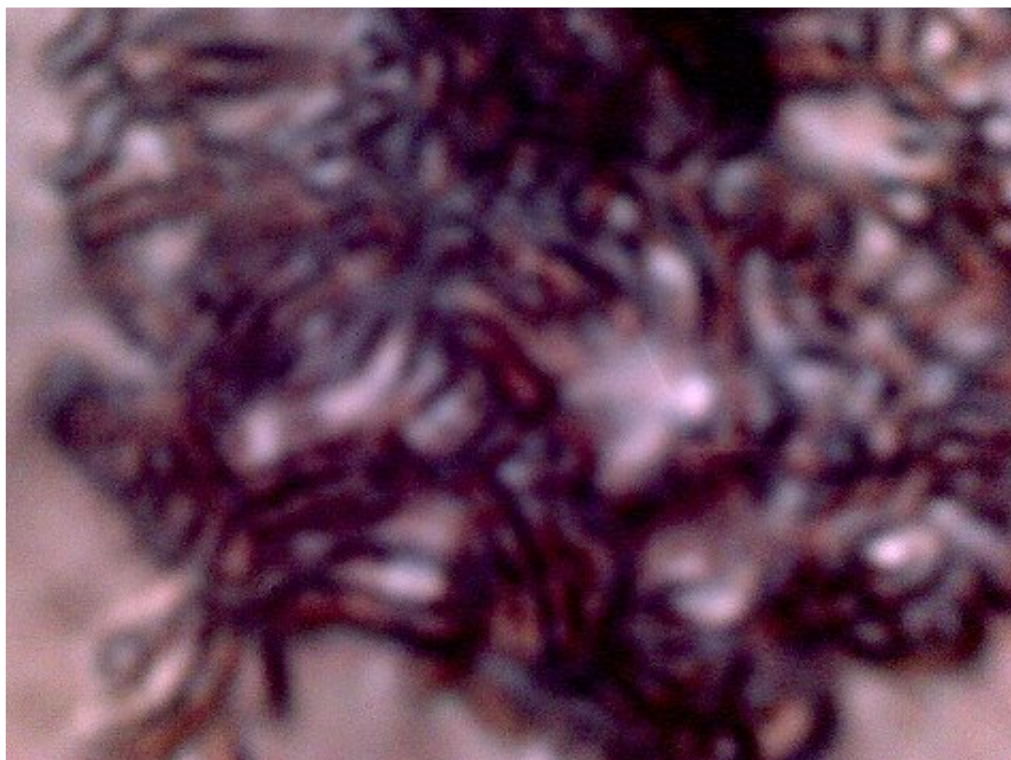
An individual that does not outwardly manifest the Morgellon' symptoms can, with sufficient internal testing, demonstrate the internal Morgellons symptoms of blood disturbance and Chlamydia-like form.



Gum-dental infectious sample subjected to the Gram stain process
 Chylamidia-like structures measure at the sub-micron level..
 This individual does not outwardly manifest the Morgellons symptoms.
 Magnification approx 7000x.

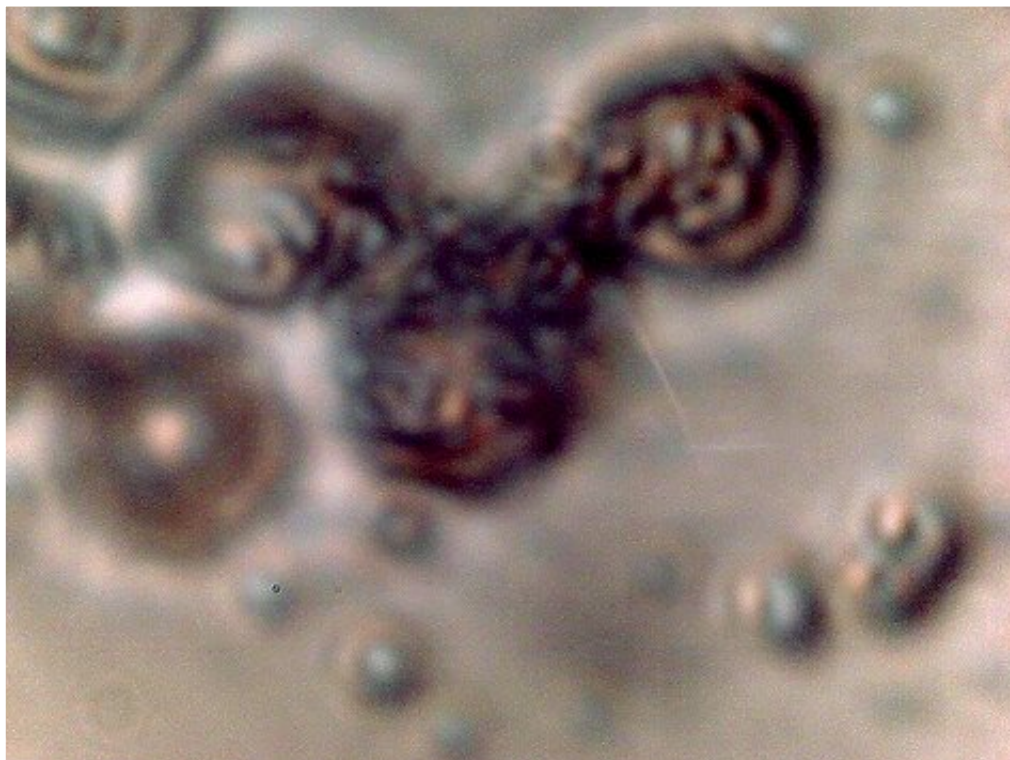


The initial stages of transformation to the *hybrid* form. Both oblate and fibrous forms are visible.
Gum-dental infectious sample subjected to the Gram stain process.
This individual does not outwardly manifest the Morgellons symptoms
Magnification approx 7000x.



Gum-dental infectious sample subjected to the Gram stain process.
The *hybrid* state is visible here, characterized by a transition to a more fibrous form.
Similarity to mycoplasma forms is worthy of consideration.

This individual does not outwardly manifest the Morgellons symptoms
Magnification approx 7000x.



Blood cells of this same affected individual that have been subjected to the Gram stain process.
(Gram stain process is expected to damage the blood cell integrity in addition to revealing gram-sensitive bacterial forms)

Numerous intracellular structures visible (Chlamydia-like).

Hybrid form also visible (mycoplasma-like also under consideration).

Equivalence of form to dental sample is apparent.

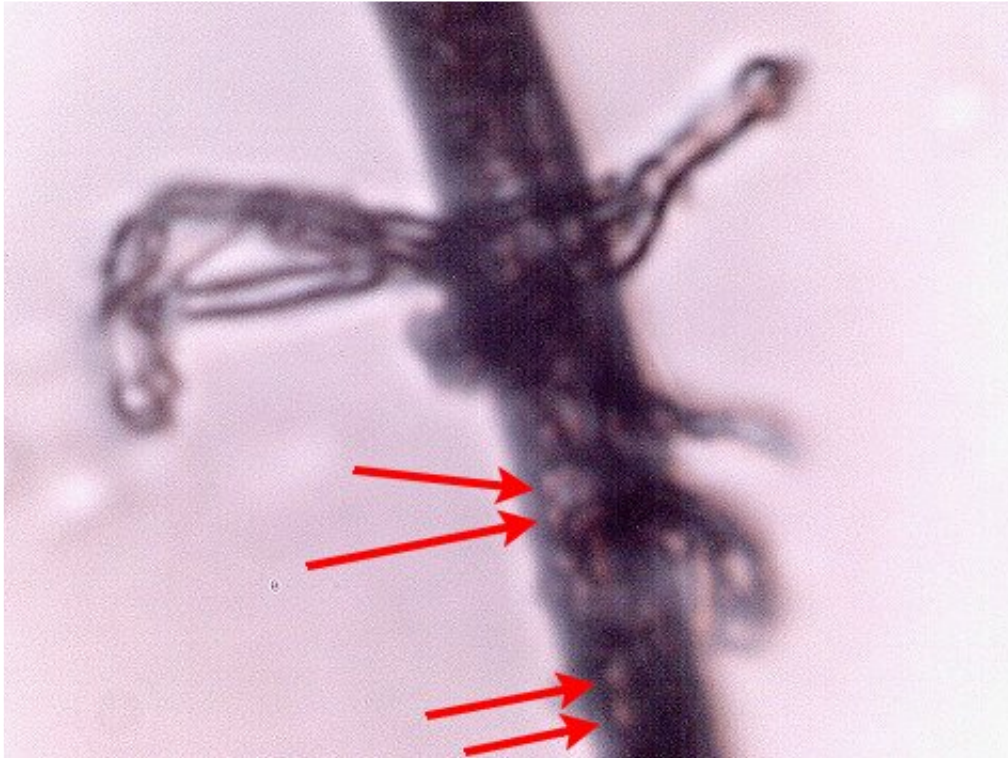
This individual does not outwardly manifest the Morgellons symptom, but bears a blood condition that appears identical to that of an individual that DOES visibly manifest the Morgellons symptoms.
Magnification approx 7000x.

The 6th Match:

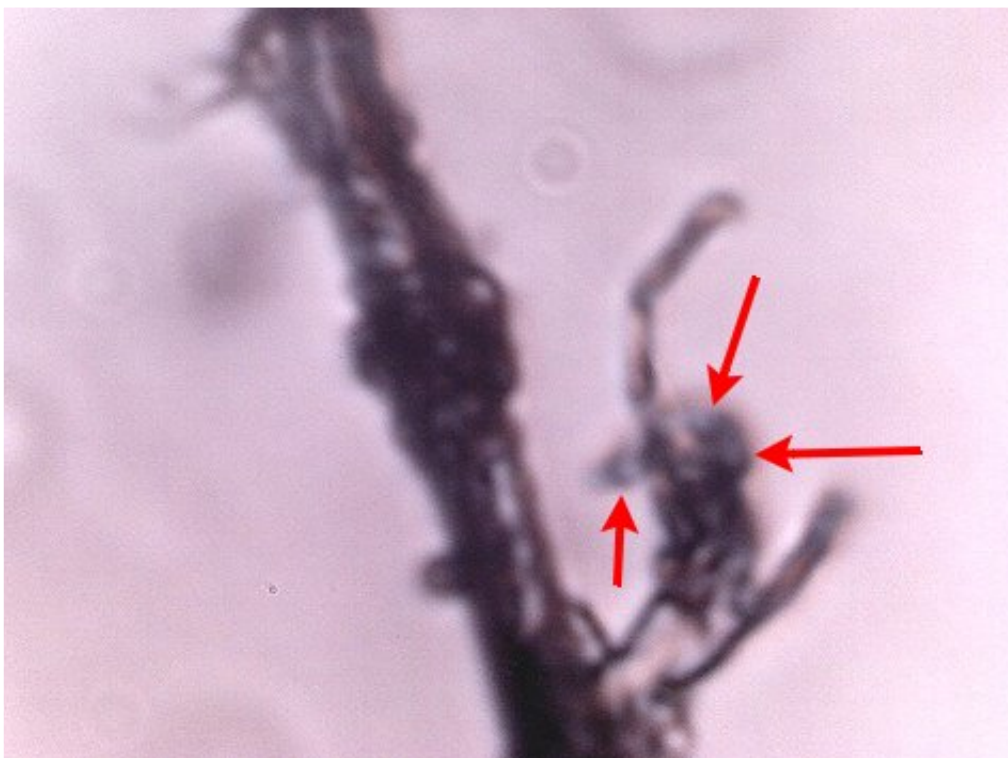The individual here is the same as that described for the 5th match (Chlamydia like structures). The individual does not outwardly manifest the Morgellons symptoms. A more detailed examination of the gum-dental sample DOES reveal the presence of anomalous fibrous forms. What is unique in this case is that the filament, as opposed to encasing a sub-micron fibrous network, instead encases the Chlamydia-like organisms. This demonstrates the real possibility that morphing between all three reported forms is frequently taking place.

The assessment that is to be made at the end of the 6th match observation set is as follows:

An individual that does not outwardly manifest the Morgellons symptoms can, with sufficient internal testing, demonstrate the Morgellons symptoms of anomalous fibrous form.



The same subject demonstrates an anomalous fibrous form within the gum-dental infectious sample. This individual does not outwardly manifest the Morgellons symptoms. Internal testing does, however, reveal identical blood disturbances, Chlamydia-like form (red arrows) and the anomalous fibrous form to that showing in an individual that DOES exhibit the Morgellons symptoms. Outward appearance, therefore, appears insufficient to identify the existence of the Morgellons condition. Magnification approx 2500x.



Another anomalous fibrous form within the infectious gum-dental sample
Notice the unusual budding forms as referenced in previous work.
Note the congregation of Chlamydia-like organisms on the bud structure (red arrows)..
This individual does not outwardly manifest the Morgellons symptoms.
Magnification approx 2500x.

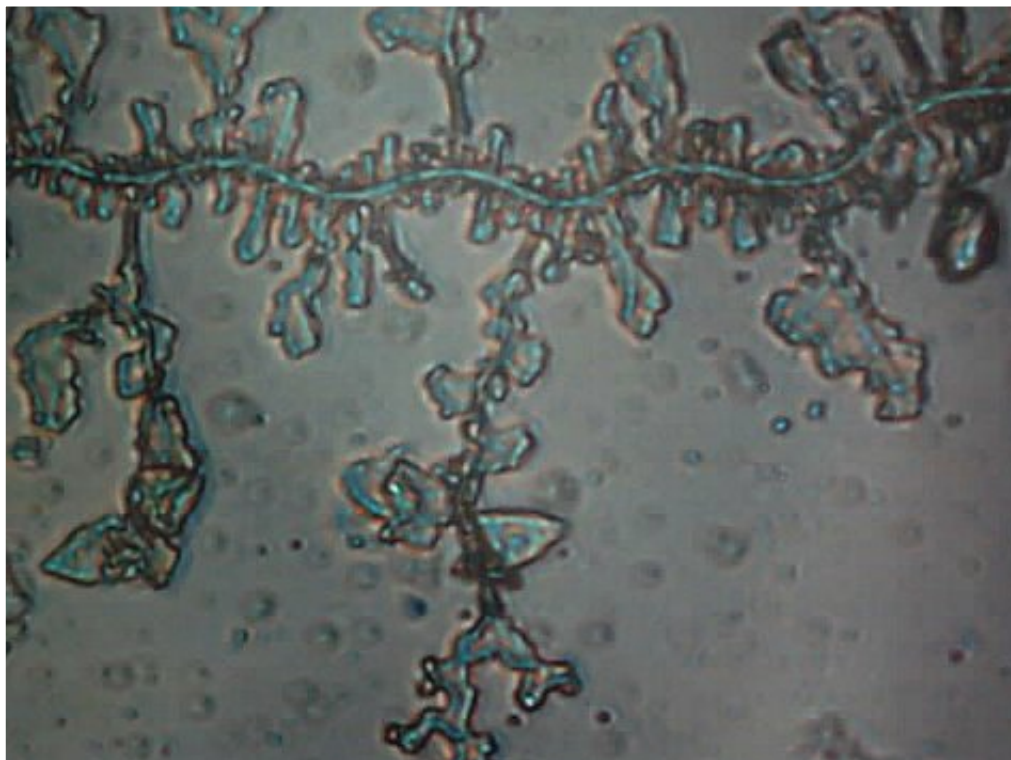
The 7th Match:

This individual manifests the Morgellons symptoms in pronounced fashion. What follows are microphotographs of the "saliva" of that individual. This individual has long declared that this mucus is highly abnormal and that it reacts to ultraviolet radiation. It is to be mentioned that the sample from the individual was extraordinarily viscous and thick, and that it required "cutting with scissors" to extract a suitable sample for the slide. The mucus was allowed to dry on the slide prior to photographing.


The assessment at this stage of analysis is:

The detected Chlamydia-like structures, filamentous and hybrid forms are being detected across major systems of the human body, including circulatory, digestive and skin. An airborne source of similar form and size has been identified. The repeated detection of airborne dessicated erythrocyte forms and subsequent extraordinary culture results must be considered in relationship to the anomalous blood conditions that are being observed on a widespread basis. It may be appropriate to investigate the filamentous form as an encapsulating, transporting, extension or delivery system of chlamydia-like and mycoplasma-like organisms. The pathogenic forms may be distributed across major segments of the general population.

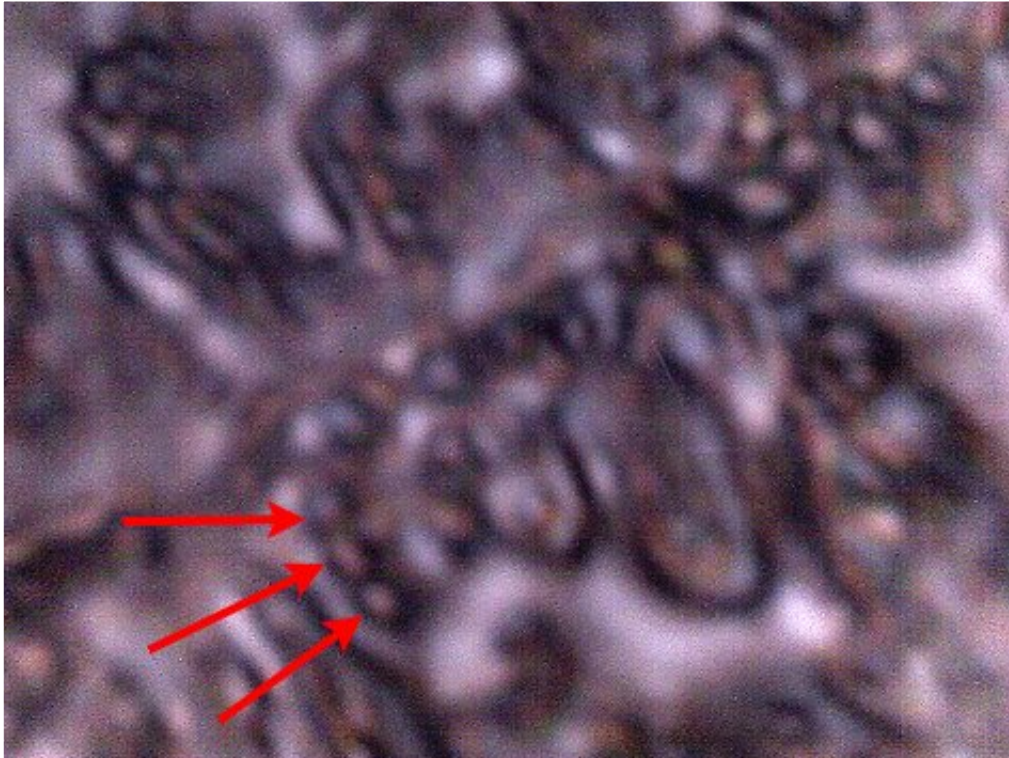
The response of the Centers for Disease control and of the U.S. Environmental Protection Agency has been and continues to be completely inappropriate and inadequate. The citizenry should not follow the scheduled restrictive and containing "response" by the CDC; the public should dictate the course along with the schedule of demands and their own expectations of progress and scope. It is not advisable to wait another year for a "preliminary" report. Any role of the military, including the participation of the Armed Forces Institute of Pathology, is to be questioned as to its impartiality and intent in any investigation. The public interest remains to be served.



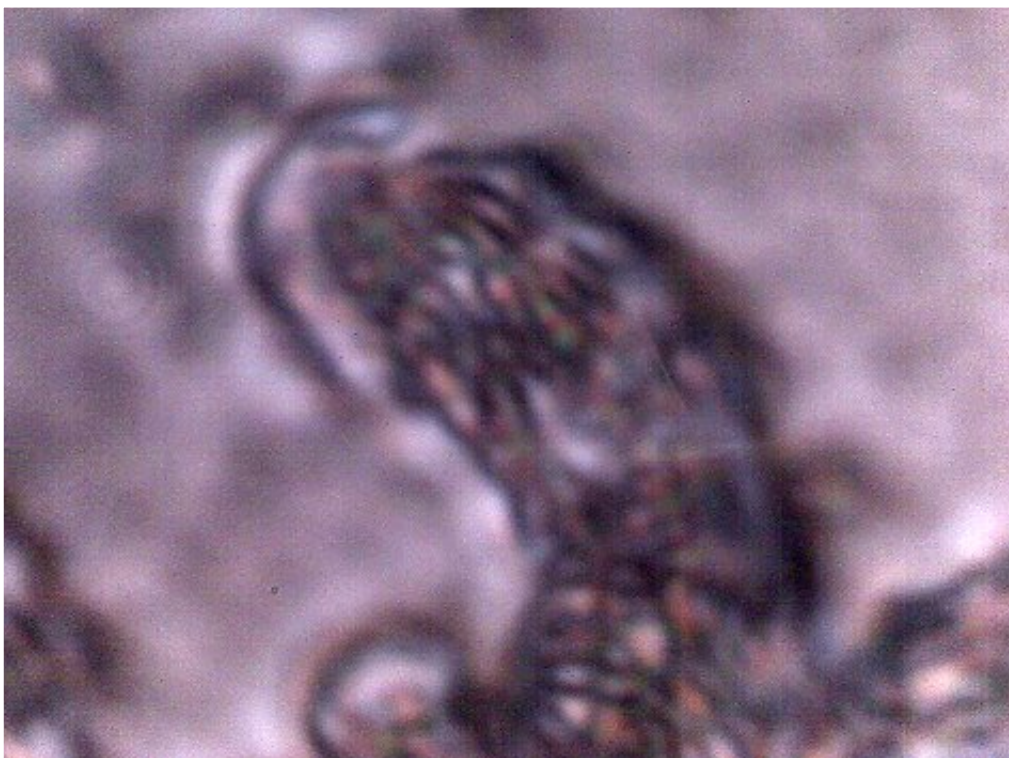
At relatively “low” magnification, the “saliva” appears to have a crystalline or dendritic form. This individual does visibly manifest the Morgellons symptoms. Magnification approx 700x.



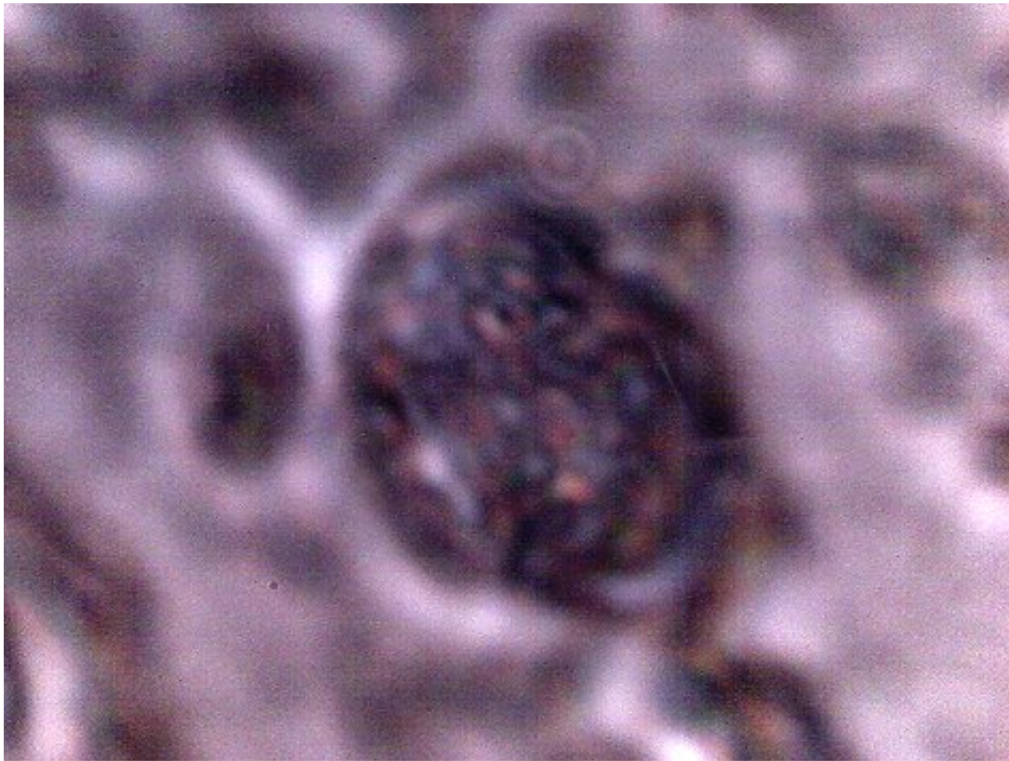
At high magnification, the dendritic forms take on increasing complex form. This individual does visibly manifest the Morgellons symptoms. Magnification approx 2500x.



At the highest magnification available, considerable internal structure is again apparent. This individual does visibly manifest the Morgellons symptoms. Identical Chlamydia-like forms are now found within the "saliva" sample (red arrows). This expands the detection of similar organisms and growth across major systems of the body, including circulation, digestion and skin. A potential airborne source of the structures has been identified. Magnification approx 7000x.



The hybrid form is visible within the “mucus” sample.
This individual does visibly manifest the Morgellons symptoms.
Magnification approx 7000x.



Both Chlamydia-like structures and the hybrid forms are visible within the mucus sample at sufficient magnification.
This individual does visibly manifest the Morgellons symptoms.
Magnification approx 7000x.

Clifford E Carnicom
January 21, 2008

MORGELLONS... A Natural Medicine Approach

Jan 27, 2008

MORGELLONS...

A Natural Medicine Approach

Posted by C.E. Carnicom on Behalf of the Author:

Gwen Scott, N.D.

Jan 27 2008

Last Edit Feb 12 2008

Timing is everything, we are told, and now seems to be the time for some revelations.

Those of you who have watched Clifford Carnicom's documentary on the aerosol operations (Chemtrails) will know me. We have worked together for many years now, trying very hard to unravel the purpose, content, and impact of what is being dumped into our air supply every day. It should be realized that because these are very small particles, they are systemic to your entire body in less than a minute. Think about that, seriously.

My interest is, primarily, finding natural medicines that can help ALL people mitigate the devastating effects of a multi-leveled assault on human health. Mr.Carnicom has provided immeasurable help in identifying contents so that I may design some natural medicine protocols around them. And make no mistake, the contents can be changed at any time without our knowledge or consent. In fact, I believe it has happened and will continue to happen without accountability.

Before I continue a few legal issues need to be addressed. New Mexico and most other states do not license Naturopathic Doctors. The law says I may educate you, but I cannot diagnose illness, or prescribe any medications. With that in mind, I am going to recount my own personal journey with Chemtrail implications as well as "Morgellons." If any of the information I present has meaning to you, please find an enlightened and competent health care practitioner to work directly with you. Many natural medicines and drugs (prescription and over the counter) do not interact very well, and in some cases, can cause dangerous contraindications. It is imperative that you work closely with a professional you trust and not try to "cowboy" your health circumstances. I give you permission to share any and all information presented here with your health care practitioner so that he/she may evaluate it in light of your own regimen and symptoms.

Also, it is important that you understand one of the founding principles of natural medicine...Herring's Law of Cure. This law presents that your body will rid itself of anything unwanted (diseases, etc.) from top to bottom, from the inside to the outside, and in the reverse order in which it entered your system. As you will see, much of the work on my own body follows this law exactly.

I am presenting both empirical (personal observation) with scientific information. Many thanks to Clifford Carnicom (hundreds of unpaid hours on his side), a research doctor, a surgeon, a chemist, and many publications for the scientific information. Although I do not have formal scientific training, I have read many books on human anatomy and physiology (structure and function of the systems) as well as herbal remedies, and all other natural modalities. I have also spent lots of hours looking into a microscope. I have a degree as a Naturopathic Doctor from an accredited college. But again, this is a journal of my personal experiences and not in any way to be understood as a "how to" remedy for the Chemtrail maladies, including "Morgellons."

I spoke of timing at the beginning. It is time to say I am the “Morgellons” person that Mr. Carnicom used for many of his blood, skin, lung, and mouth samples. At the beginning of this work, I was the only provider. Now with so many people willing to give him samples, I know his work will continue. It is time for me to step forward.

I will get to what is being called “Morgellons” disease in just a minute. I must say, in my opinion, it’s not really a disease in the traditional sense. It is not measles or mumps. It doesn’t run a finite course nor is it exclusive to contact with other humans. What we are looking at here is an inorganic fiber and other components delivered through the air supply. In my opinion, what we are really looking at is a progressive “system” or “syndrome” in which “Morgellons” is just the latest and most visible aspect.

My journey into this “syndrome” began over ten years ago. I felt “something” was in me that didn’t belong...a gut feeling. I also noticed that my joints were aching more than they should, I got tired easily, I was getting skins breakouts, and my digestion was “off.” I was eating well (organics, free range meats, etc.) and exercising, yet I felt my vitality slipping. I decided to begin a program of “wellness” without any idea where it would lead me.

I began by introducing herbs and herbal combinations that would address the full range of pathogens that might be causing me problems...bacteria, virus, fungus, and parasite. I was able to eliminate organic parasites at the beginning. That still left me with the other three. So, I searched for and found one herbal combination that addressed all three. It is called Deep Health by Herbs, Etc. I also made some bad or aggressive choices that were really quite dangerous which I will not share. With this herbal extract I began to get sores all over my head, but, mindful of Herring’s Law, I saw this as a good thing (top to bottom, in to out) They were painful, numerous, volcano like, and produced scabs that were very itchy and would not heal for weeks, months, and, in one case, two years. Of course, at the time, it was before Chemtrail awareness, so I assumed something from earlier years was coming out or some new disease I didn’t know was presenting (later I was to look at photos and see the lines in the sky that I was unaware of at the time.) Those sores were exactly like the ones I have today on my back, but I cannot tell you if there were fibers in the scabs. I strongly suspect there were.

One thing that is very interesting. After my scalp finally healed my hair got thicker, the few gray hairs I had fell out, replaced by much darker hair. Also, the texture of my hair changed. Instead of straight, fine hair it became more coarse and wavy. I don’t know why to this day, but I took it as a good sign. I have a client in Los Angeles who I began working with about 8-months ago and he reports that his once gray eyebrows are now brown again. He also says his once brown hair is growing in again...that he has brown roots in his white hair. Again, I take this as a sign of renewed health.

I began to look at what was happening very carefully. Surely this was not a “normal” or known situation (ten years ago.) I started to see a “network” under my skin that looked like it might be fungal in nature. I contacted a good friend who is a research doctor to get his opinion. Strangely enough, he and his research partner had been looking at live blood samples under an atomic microscope and observed a fungus in EVERYBODY’S blood sample, including his own (note: Mr. Carnicom is finding fibers and an unknown, perhaps bacterial, form in everyone’s blood as well.) He was very upset because he said it looked “altered” and was using very fine particulate metals as weapons against the immune system. He said the fungus actually collected heavy metals and “stabbed” all immune responders. It sounded so science fiction to me at the time. He told me that he had found a great metal detoxification method using food grade diatomaceous earth that he took everyday in distilled water (perma-guard.com.) He said about one tablespoon would work for most adults. The FDA doesn’t give approval for taking diatomaceous earth internally in humans, but we can give it to our cats, dogs, cattle, pigs, sheep, goats, etc. Most feed stores carry it. The only known contraindication is if it is taken with food. It will not

recognize what metals are good for you (iron, trace copper, etc) and what ones are harmful. My research doctor friend says it will bind up metals and carry them out of your body. I do know this therapy is widely used in India (white earth,) especially by pregnant women. I met the head medicine man of the Shoshone Indian People and he told me they have historically used it to detoxify people. I also met an African American healer in Georgia last year and he told me they'd been using it in his community for years, all the way back to the days of slavery.

At this point in my journey I realized that I not only needed to get rid of any metals in my system, but I needed to go on an aggressive anti-fungal diet with supporting herbs. I made sure to eat LOTS of garlic, onions, etc. and I avoided ALL sugars. I drank Pau D' Arco tea daily and began to see some important results. I also found a wonderful anti-fungal herbal combination that is no longer available, but Herbs, Etc. has a similar one called Yeast ReLeaf. It should be said, I have no financial ties with any of the companies I mention in this journal.

I continued to eat organics, drink distilled water, and eat, moderately, only free range meats. And I began to notice some vitality returning with the anti-fungal focus. But, I also knew that I was far from "clean."

About eight years ago I became sadly aware of the Chemtrails. I was blessed to be introduced to Clifford Carnicom, who at that time was a voice in the wilderness. He began to share with me all of the data he was gathering and I began to see why it was so important to get those metals out of the system. Recently, the National Institute for Health in Washington, D.C. released a report on barium. The report linked barium "intoxication" to M.S., ALS, and other diseases of "unknown" origins. The report also said that the military sprayed barium in the air! That was certainly interesting to me. A good deal of research is available linking aluminum to Alzheimer's disease, especially when the aluminum is combined with fluoride.

Also recently, an oncologist in Italy, Dr. Tullio Simoncini, says he believes cancer is really a fungus. Many other doctors came out in support when he was attacked for presenting his work. He is currently treating people with cancer with enormous success (www.cancerfungus.com). I personally think he is on the right track and so does my surgeon friend who tells me they are opening people up and finding them full of fungus.

He told me there are times they can't even find the organs because they are "covered" with fungus. I personally have not seen this, but this surgeon has years of experience and no reason to mislead me. I think a strong anti-fungal diet is a great idea. There are many books at the health store outlining them. I should say, most of the books are focused on Candida Albicans, a common fungus and we may be looking at a different "breed" here, but it's a good start.

I have also found anti-fungal soaps of great help. The brand called Miracle II and its companion Neutralizer have been invaluable in my healing process (www.miracle2.net). Most health stores carry anti-fungal soaps, usually with Tea Tree Oil.

About three years ago, I began to get open, painful sores on my back...they remain to this day. Old ones, in time, will close up and I will think I am finished, but new ones will appear, sometimes overnight. This is the "Morgellons" aspect of my journey. It wasn't until Mr. Carnicom put the scar tissue under high magnification that the true nature of these sores came to light. In every scar tissue they was at least one and sometimes many fibers. Now I began to understand why the process was ongoing. I breathe...fibers are in the air supply...body wants them out. So, I stand alone, at this time, with the following theory...Morgellons is NOT a disease in the conventional sense. It is the body's HEALTHY response to an invader, or foreign matter, that does not belong. It seeks to push it out.

About one month ago my teeth started aching. It was slight at first and I really didn't pay attention. About 4am one morning I awoke with the most painful "tooth ache" I could imagine. I tried every remedy I knew to no avail. I "talked to the kingdom" and got the answer to rinse the tooth vigorously with red wine. I certainly wouldn't have thought of that. The results are on Mr. Carnicom's web site. I continue to "pull" them out everyday with the red wine therapy and, although not as many are coming out, I am still producing. It would be an interesting test to run for yourself to see if you have fibers in your gums. Many of my friends who do not have a single "Morgellons" symptom have done it and in all cases fibers can be seen in the sink. Another interesting test is to take your temperature (digital is the fastest) everyday. Everyone seems to be running lower than the 98.6 average. Some of my clients are down in the 94-95 range.

We now know that combined with these fibers are a pathogen that has yet to be identified. It appears to cause damage to the blood, consequently all body systems. I keep hoping that someone with some expertise in this field will step up to the plate and help Mr. Carnicom with his efforts. You know, if you breathe...or your children breathe...or your mother breathes...time to understand that ALL humans are involved.

Another component that is also part of the "Morgellons syndrome" is a luminescent material that some call plastic, others silicone. It comes out of the lungs, eyes, skin, and mouth. My tears are very sticky, a recent development. The material "glows" under a black light and is unknown in its properties. Also, its purpose is unknown as well. I do know that it has somehow incorporated into what is leaving my body. It also contains the unknown pathogen seen in the fibers.

I was interested to note that as I drove across the country recently, in three different states a large "glob" of perfectly clear material hit my windshield (not a gift from the birds.) When I tried to clean it off with my wipers it smeared and took many passes to finally clear. I didn't collect any samples, but it wouldn't be surprising if this material coming out of my body is one and the same.

Also of interest to me, on CNN Anderson Cooper presented a series called Planet In Peril and one of the segments contained the results of a blood test he had taken. It was reported that he had an unusually high amount of "plastic" in his blood...wonder if we all do.

I do know that a scientist named Marcel Vogel was experimenting with luminescent materials and their uses in the 70's (Secret Life of Plants.) He later went to work for IBM and there are many patents with his name involving luminescent material. I was particularly interested in the one involving Electro-luminescent materials, but couldn't get into the data.

Another curious phenomenon...EVERYBODY'S eyes I have examined under a black light reveal that their pupils "glow" or are luminescent. Is this normal? Perhaps an expert can tell me, as I remember black light parties in the 60's and I personally don't remember pupils glowing.

Another interesting observation...after the sores finishing expelling blood with fibers, the scar tissue becomes "plastic" which also contains the fibers.

One final note. There is a huge assault on all life forms taking place electro-magnetically. The planet and all life on it evolved, together, with a common electro-magnetic field. We know from Mr. Carnicom's work that new frequencies of many levels are being introduced into the atmosphere. How can this not affect us? We are electro-magnetic beings. Could these new "waves" be causing the epidemics I see in depression (NBC reported that nearly ONE-HALF of all Americans are taking anti-depressants,) sleep deprivation, tinnitus (ear ringing,) and memory loss? A physicist told me that some of these new

frequencies correspond to the same frequencies in the brain that control sleep, mood, and memory. What “materials” are in our body that might respond to these frequencies as well? I certainly don’t know, but it is worth considering when taking a holistic approach to wellness.

FINAL OBSERVATIONS

So, as far as I can observe, we are dealing with a highly integrated “system,” not one disease called “Morgellons.”

And, as I have indicated, it needs to be addressed on a number of levels...heavy metals, fungus, diet, etc. I know you cannot hope to heal eating processed, denatured, chemically rich foods. It has been suggested that perhaps some of what we are looking at here actually comes into us through our food supply. I don’t know. Consider what you put in your mouth very carefully...does it heal or harm? If you are serious about being well during these times, you really have to look at your diet. “Food is your remedy, your remedy is food” Hippocrates.

Fungus is a major player...so are fibers, a bacterial form (mycoplasma, etc) and luminescent materials. There might be others as yet unseen. A research doctor is sure we also have nano-technology in there as well. Although I haven’t observed any in the blood samples, I wouldn’t be surprised. Many of the national labs are spending a lot of money and research on nano-technology. Some of the titles of the studies are very unnerving.

I have another observation based purely on my own physical experience. The more I rid my body of these unwanted materials, the more people tell me that I am looking younger. My hair is thick...I have lost about 10-pounds that I simply couldn’t get rid of...they just feel off and I am returned to my “normal” weight. My eyesight has improved dramatically...20-250 to 20-150 in a year and the process continues. Many of the “age” lines on my face have disappeared and my previously achy joints don’t bother me at all. Could it be that these materials are designed to age us rapidly? I have heard lots of people talking lately about how their friends and family members are getting old quickly. I have noticed it myself. Could the agenda presented years ago to thin the population be in full swing (read “....and the truth shall set you free by David Icke.) It seems like it to me.

A final word to anyone involved in spraying our skies...even if you think you are doing something good for the citizens of the world...you are not. And if you and those you love breathe...well then, someone has mislead you. I believe in time we will find that EVERYONE has “Morgellons” syndrome. That EVERYONE, whether they are presenting sores or not, is carrying fibers, fungus, luminescent material, etc. Mr. Carnicom’s most recent work would certainly lead us in that direction.

Again, work with a professional who understands and has the expertise to help you towards wellness.

I will update this journal with new information as it appears.

Stand in The Light

Blessings and Good Health

Gwen Scott, N.D.

Update

Gwen Scott, N.D.

Many thanks to the gentleman with scientific information who contacted me regarding my paper.

He told me that black lights have “short” or “long” waves. He said the short wave type is harmful to the eyes if a person looks into it for a period of time. He also told me it should be labeled either “short” or “long” wave on the tube. So, if you are going to look into your eyes, or use the black light on another person, please make sure it is a “long” wave light.

Another point from this gentleman...he said I really should be using the term “fluorescent” instead of “luminescent” when describing the material that glows. As it seems to reflect, rather than generate light, I think it makes sense.

I thank everyone for the feedback and look forward to some more scientific input. I know Mr. Carnicom has been waiting for help on his end as well.

I would like to emphasize again that Herring's Law of Cure is very important in this process of clearing the body of unwanted “debris.” Once again, be thankful if your body has the health and strength to push fibers, “plastic,” and other unwanted invaders out of you. We have been trained to believe that any “outbreak” should be immediately suppressed. In natural medicine the opposite holds true. We see this process as a sign of a healthy immune system and strong “chi.”

Finally, a few years ago I wrote a general paper for this site with specific suggestions for mitigating “Chemtrail” sickness. Although new information and scientific findings have come to light, the presentation could still be of help to you (Natural Medicine For These Times.)

“Get Onboard” Dorothy Love Coats Gospel Singer

Many Blessings and Good Health

February 9, 2008...Quick Update

I discovered this morning that combining a few therapies can increase the productivity of the wine/teeth therapy quite a bit.

For a few years now I have taken three to four Q-tips soaked in hydrogen peroxide and gone around the area where my teeth meet the gums. I follow this with flossing and rinsing with the Miracle II Neutralizer. Today I immediately followed that therapy with the vigorous swishing of red wine and was astounded at the rate of production. The amount of material (fibers) expelled was at least four to five times more than I get using the wine therapy separately. You might want to give it a try.

Many Blessings

Gwen Scott, N.D.

[Editor's Note: A major portion of the recent research on the Morgellons issue has been made possible through the kindness, generosity and the unselfish contributions from Gwen Scott, N.D. Eternal gratitude is extended to her for the help and assistance that she has offered to the public and to you. We continue to do the best that we can with the means and resources that are available to us. CEC]

Mar**MORGELLONS: PATHOGENS & THE GENERAL POPULATION**

Mar 8, 2008

MORGELLONS:**PATHOGENS & THE GENERAL POPULATION****Clifford E Carnicom****Mar 08 2008****Last Edit Apr 09 2008**

I have no medical expertise and I claim none. I am not offering any medical advice or diagnosis with the presentation of this information. I am acting solely as an independent researcher providing the results of extended observation and analysis of unusual biological conditions that are evident.

There is increasing evidence that the general population may be affected by at least four pathogenic forms. Any perception that only a small segment of the population is affected by the so-called Morgellons condition may be quite false. Certain pathogenic forms are repeatedly showing up in a majority of human biological samples that have been observed, regardless of whether or not visible skin anomalies appear. The use of unusual skin conditions as a defining criteria of the existence of the "Morgellons condition" appears to be completely inadequate and it does not appear to encompass the severity, extent and distribution of the pathogenic forms.

The pathogenic forms are as follows:

1. An encasing or encapsulating filament, often barely visible to the human eye. This filament form often measures on the order of 12 to 20 microns in thickness. This bounding filament form usually contains within it a network of sub-micron fibers that are generally in parallel alignment with one another. This filament form has been found within airborne, skin, saliva, gum(dental) and ear wax samples. It has also been observed within an anomalous hair sample. It appears possible that the function of this particular form is to deliver or encase a sub-network of additional pathogens of much smaller size. No natural identity of this form has been established.

2. A network of sub-micron filament forms. These are usually encased within the bounding filament referred to above. A human hair is on the order of 60-100 microns in diameter; an asbestos fiber is on the order of 2 microns in thickness. This pathogenic form has repeatedly been found within airborne, skin, saliva, ear wax and gum(dental samples). This form has some morphological similarity to fungal forms (i.e., hyphae) but no suitable match to any known species exists at this time. In addition, there is no match at this time to a eukaryotic cell structure which is required for a match to fungus. A "budding", or apparent growth structure composed of filaments of this same class has been identified on skin borne biological samples. A method for the testing of chitin, usually present in the cell walls of fungi, is to be established.¹

3. A sub-micron spherical to oblate structure. The best size estimate for this form is currently on the order of 0.5 – 0.7 microns. These structures can and often do occur in large numbers within the biological samples. They have been found in isolation within the bounding filament as well as in large concentrations within the bounding filament. They have been found in combination with the sub-micron fibrous network within the bounding filament. They have been found in airborne, skin, saliva, ear wax, gum(dental) and anomalous hair samples. They have been found within a broad distribution of human blood samples. They can and often do exist as an intracellular(within the cell) organism. The damage to

cellular integrity(i.e, erythrocytes, or red blood cells) appears to correspond directly to the numbers present of the organism. The best assessment to date that can be offered by this researcher is that of a Chlamydia-like(coccus) bacterial form, with special a emphasis upon Chlamydia pneumoniae. The modification of conventional biological forms or of pathogens to exotic levels should be strongly considered throughout this investigation, in addition to the creation of new or unknown forms. The structure stains Gram-negative.

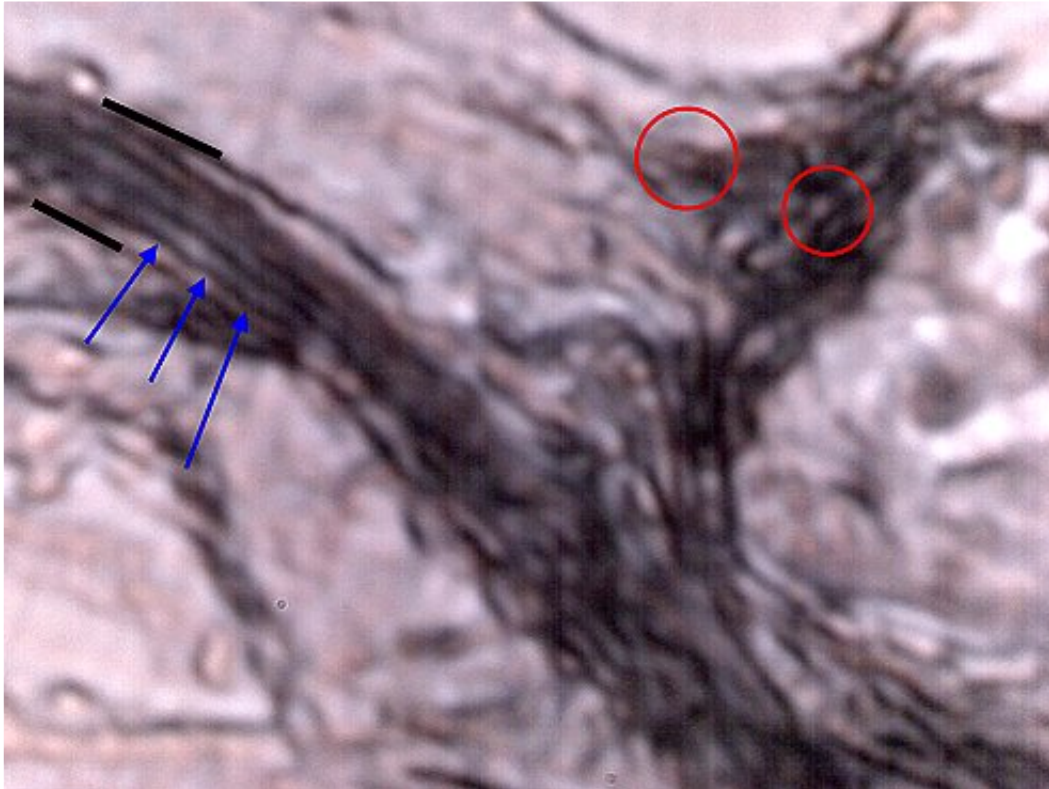
4. What is being called, for the time being, a “hybrid” form. This form has properties that are somewhat in between the sub-micron Chlamydia-like form and the sub-micron filament form. This form appears to be a state of transition between the two more defined sub-micron forms. It has been found only in biological samples and not in airborne samples. It occurs commonly within, but it is not restricted to, human blood samples and it often is in association with the Chlamydia-like form. It is of generally filamentous form but it is reduced in length compared to the sub-micron fibrous network that has been itemized. Mycoplasma or Mycoplasma variations or modifications are one consideration within this topic.

Readers will find numerous microphotographs of the mentioned forms on a series of papers that have been recently presented on this site, as well as in the examples presented below. These pathogenic forms were first and originally identified within two subjects that manifest visible “Morgellons” skin symptoms, and it may have been surmised that such pathogens are restricted to that class of individuals.

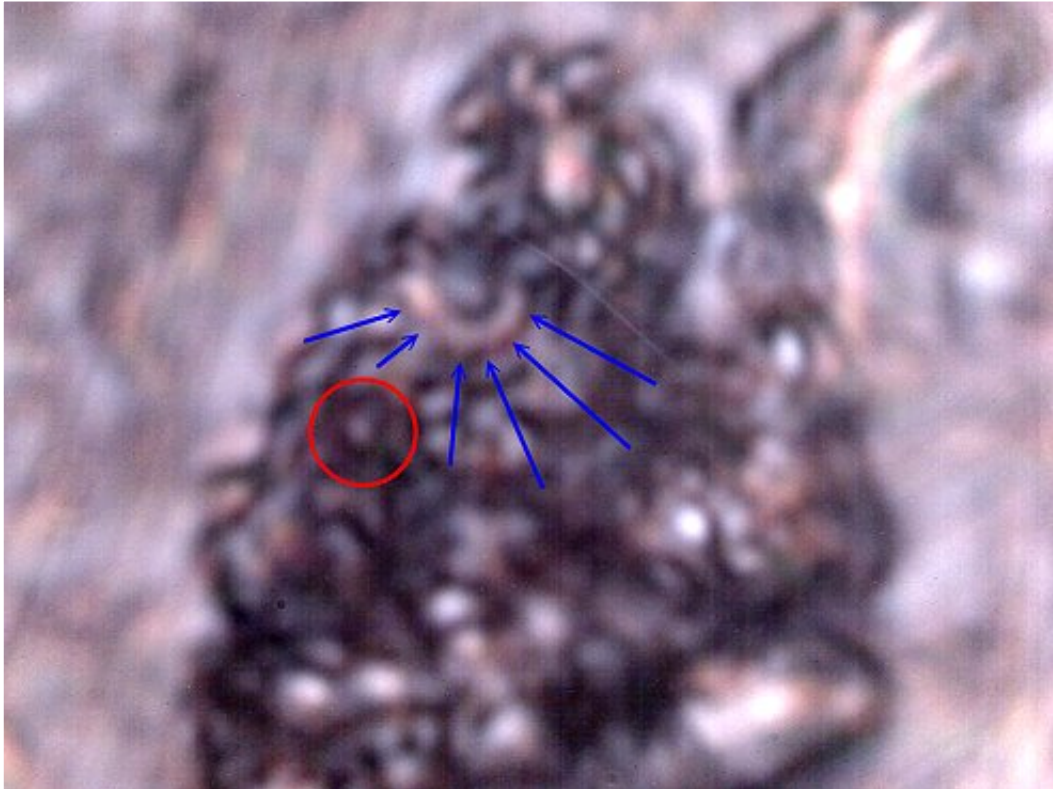
The remainder of this paper will present evidence that visible skin anomalies are not a suitable criteria to establish the existence of the so-called “Morgellons condition” and that certain pathogenic forms may be repeating internally within a broad cross-section of the general population. The results from four individuals will be presented. These individuals were selected essentially at random and they possess NO VISIBLE SYMPTOMS that are commonly being reported as characteristic of the “Morgellons condition”. Every individual that was tested in the manner of this report(gum-dental & blood) demonstrates the existence of these pathogens within their body. The prevalence of the four [SEE NOTE BELOW] pathogenic forms in all cases thus far appears to be indiscriminate as to age, sex, or the general state of visible health for that matter. It appears that the “Morgellons condition” has been defined primarily in terms of anomalous and visible skin conditions; it is apparent that this restriction is artificial and essentially meaningless with respect to the existence of the pathogenic forms described here. The only correlation that may be made with visible symptoms appears to relate to the number or extent of pathogens that are present in the body.

Put more bluntly, the general public may wish to become engaged in this issue.

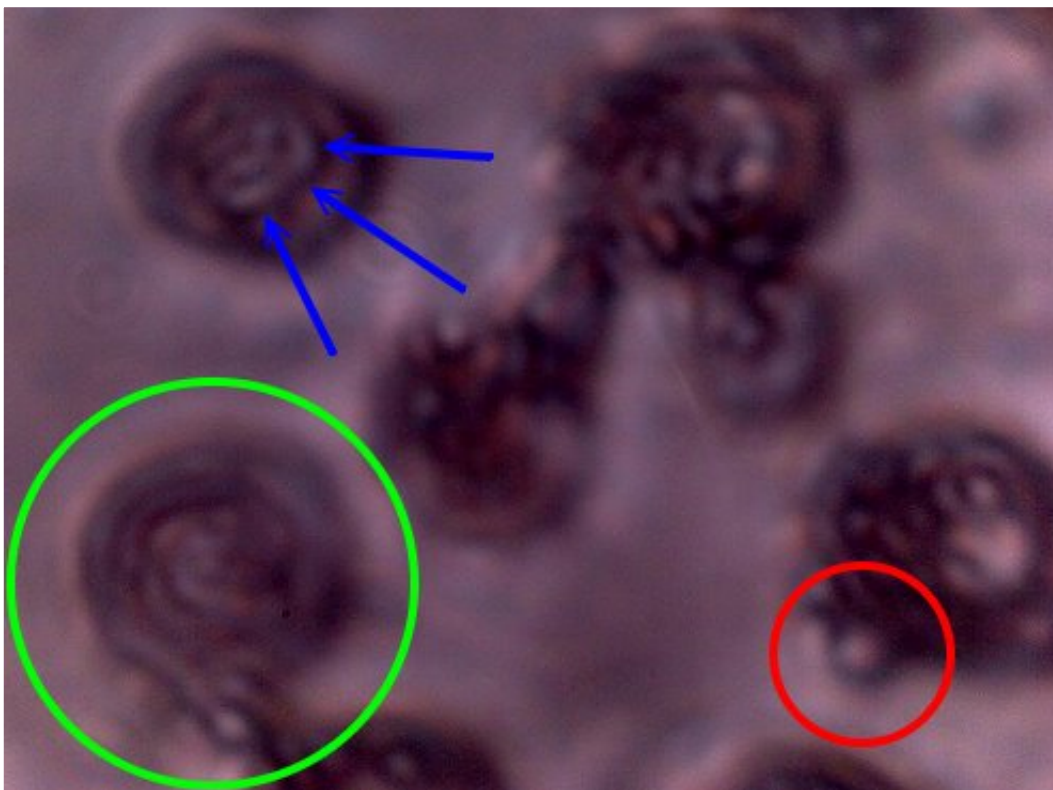
The following is a set of microphotographs from individuals that do not display any visible symptoms (i.e., outwardly visible) of the so-called “Morgellons condition.” These photographs are at high magnification and they are at the limit of visible microscopy.



Subject No. 1. Male subject aged 55 years. No visible “Morgellons” symptoms. Dental-gum expelled sample. Sample extracted with use of hydrogen peroxide-red wine mix. (please refer to [Morgellons: A Natural Medicine Approach](#), by Gwen Scott N.D.) Three pathogenic forms visible: bounding filament (black border), sub-micron interior filament network (blue arrows) and Chlamydia-like organisms (red circles). These same pathogenic forms repeatedly found in an individual with visible skin anomalies characteristic of the so-called “Morgellons” condition. Magnification approx. 7000x.



Subject No. 1. Male subject aged 55 years. No visible "Morgellons" symptoms. Dental-gum expelled sample. Sample extracted with use of hydrogen peroxide-red wine mix. Chlamydia-like organisms visible (red circle) and "hybrid" form (blue arrows). The Chlamydia-like organisms measure at approx. 0.5 microns. Magnification approx. 7000x.



Subject No. 1. Male subject aged 55 years. No visible “Morgellons” symptoms.

Blood sample that has been subjected to the Gram stain process to identify bacterial forms.

Erythrocyte (red blood cell)(green circle) cell structure is expected to and will deteriorate as a result of the stain process.

Unstained erythrocytes measure on the order of 6-8 microns.

Chlamydia or Chlamydia-like organisms(red circle) are evident and more readily visible as a result of this stain process.

They can, with careful observation, be observed to disrupt the topography or surface of unstained blood cells;

this is a further indication of the intracellular property of the organism.

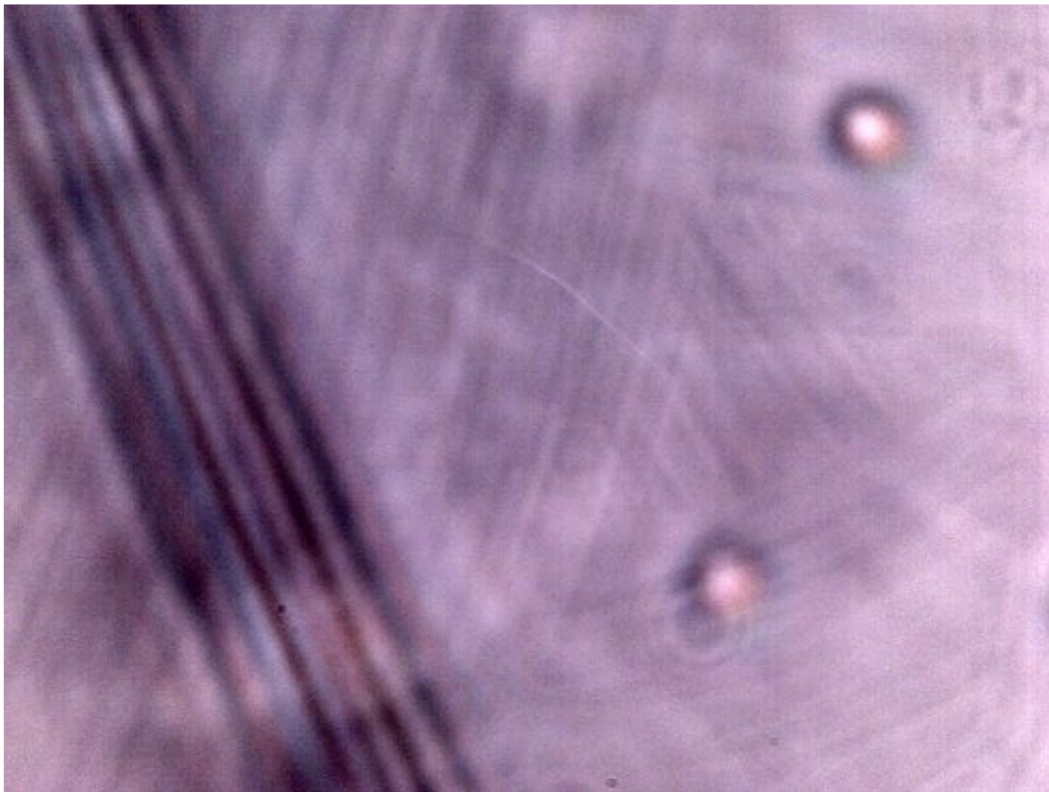
Chlamydia-like organisms measure on the order of approx. 0.5 – 0.7 microns.

Hybrid form also visible in this stained sample(blue arrows).

Organisms are intracellular, i.e, they exist within the cells.

Bacterial infections within the blood can be of grave consequence.

Magnification approx. 7000x.

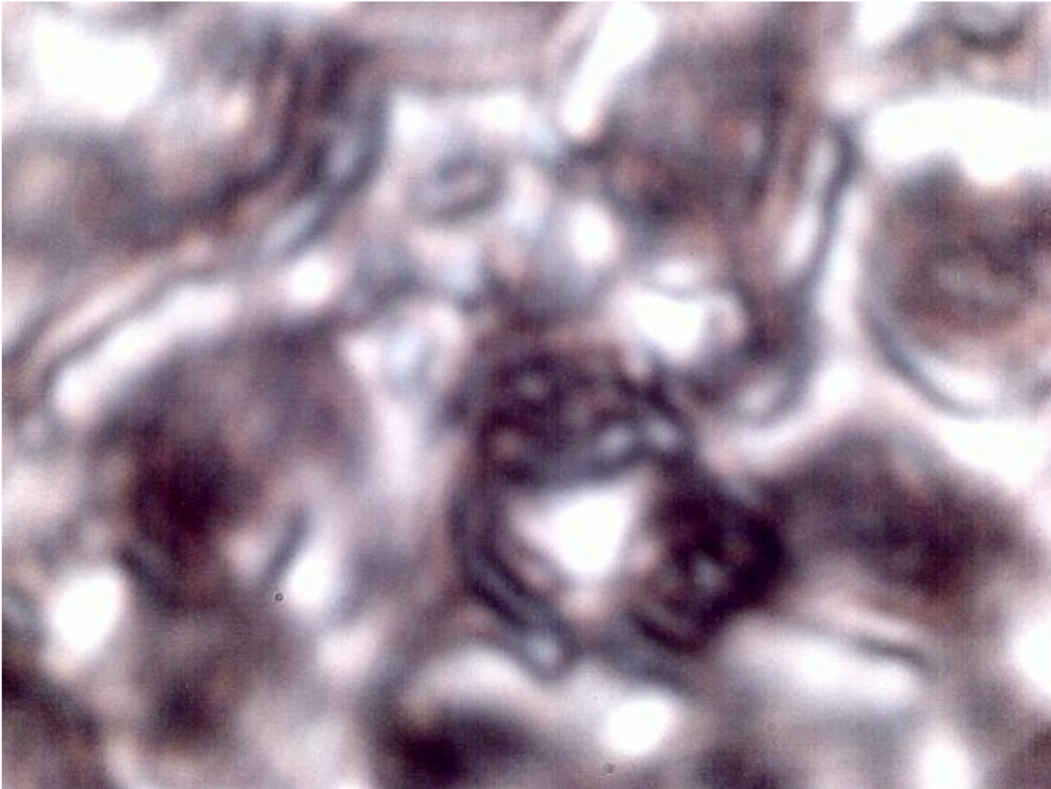


Subject No. 2

Male, approx. 60 years.

Dental sample. Encasing filament and sub-micron fibrous network.

Magnification approx. 7000x.



Subject No. 2

Blood cells subjected to the Gram stain process. Blood cell structure is damaged as a part of the stain process

and the Chlamydia-like structures become visible as a result.

Magnification approx. 7000x.



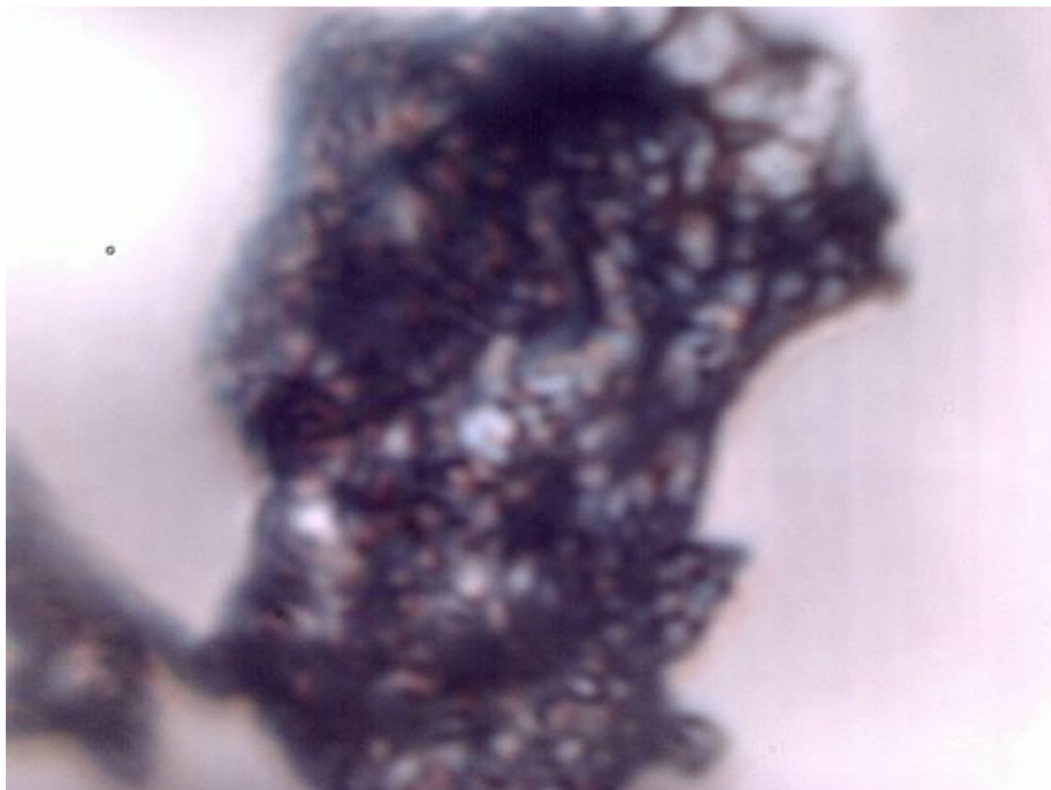
Subject No. 3

Female, 60 years.

Dental sample. Encasing filament and sub-micron fibrous network.

Magnification approx. 7000x

.

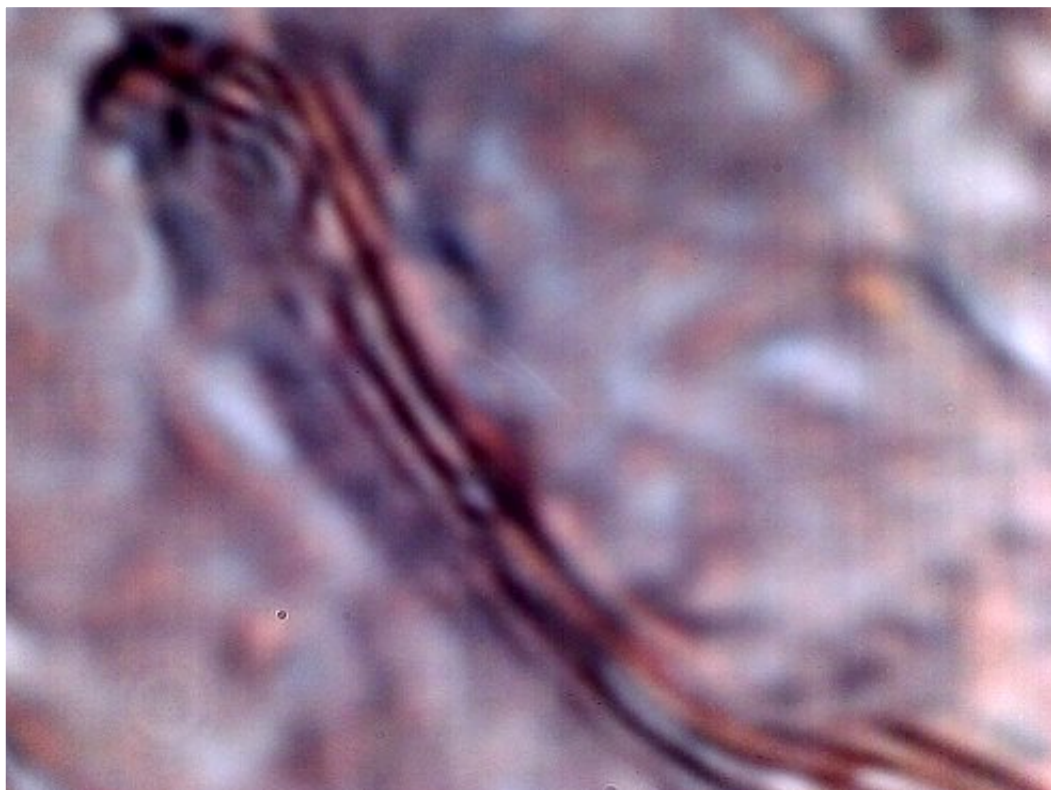


Subject No. 3

Female, 60 years.

Dental sample. Extensive collection of sub-micron Chlamydia-like structures..

Magnification approx. 7000x.



Subject No. 4

Female, approx. 60 years.

Dental sample. Sub-micron fibrous network.

Magnification approx. 7000x.

Additional Notes:

Twenty-six, not four, individuals as a minimum have now subjected themselves to the sampling method of this report. The sampling process now crosses numerous state lines, including New Mexico, Colorado, North Carolina and Montana. Twenty-six of the twenty-six subjects show the same pathogenic forms. The above photographs document only four of the fourteen individual samples. Most of the individuals show no outwardly visible forms of affliction. The only variance is in the amount of material that exists or is produced within the body. Visible skin signs of the "Morgellons" condition are not a suitable criteria to establish the existence of the pathogenic forms in the body. The evidence supports the contention that the general health of the population has been seriously compromised by the pathogenic forms under examination.

My time available for research and the presentation of the information remains limited. This website exists on a month-to-month contract. The existence of this website is not guaranteed. There is no known independent off site copy of this website. The public should preserve, protect and distribute the information on this site to their own level of confidence and assurance.

Clifford E Carnicom

Feb 13 2008

Edit Apr 09 2008

References:

1. Chemical Analysis for Chitin as a Measure of Fungal Infiltration of Cellulosic Materials., Army Mobility Equipment Research and Development Command, Fort Belvoir, Defense Technical Information Center, Access No. ADA036986, <http://www.dtic.mil/dtic/tr/fulltext/u2/a036986.pdf>

"MORGELLONS:" THE WINE - PEROXIDE TEST

Mar 9, 2008

"MORGELLONS:"

THE WINE – PEROXIDE TEST

Clifford E Carnicom

Mar 09 2008

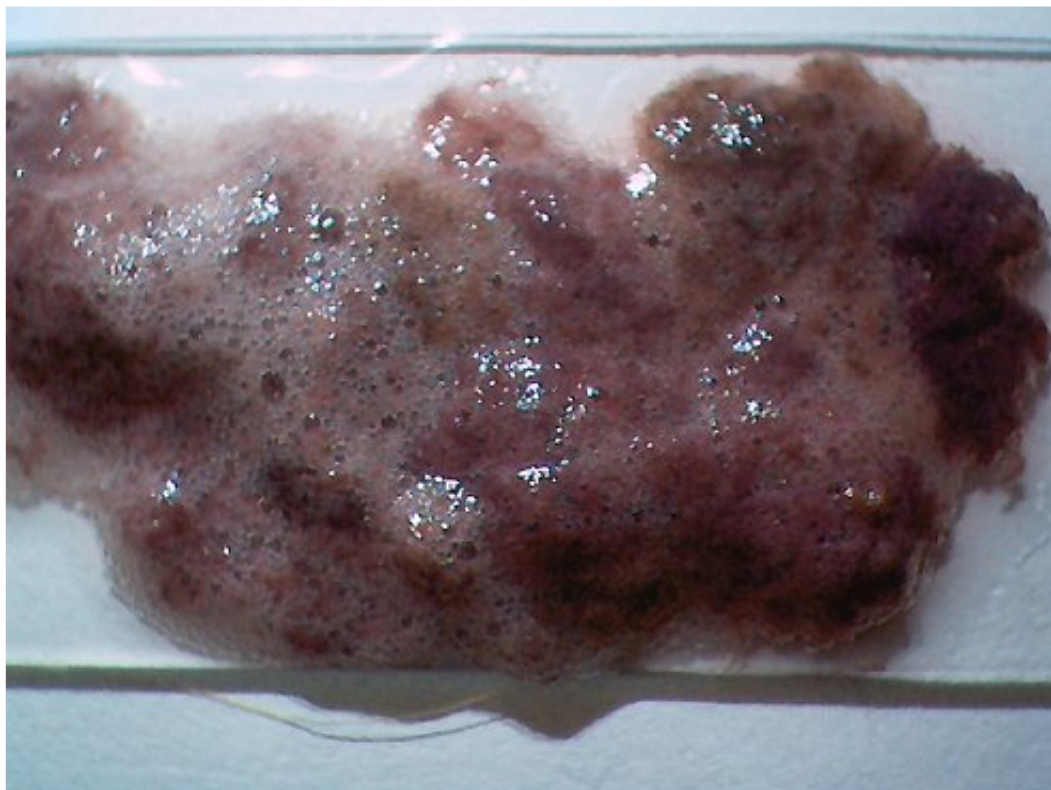
Last Edit Mar 15 2008

I have no medical expertise and I claim none. I am not offering any medical advice or diagnosis with the presentation of this information. I am acting solely as an independent researcher providing the results of extended observation and analysis of unusual biological conditions that are evident.

The following photographs are not pleasant to view and I would prefer to not have to present them. The magnitude of the issue demands that the information be made available to the general public. A method to remove at least a portion of the pathogenic forms that have been reported extensively on this site has been established. The method involves the use of red wine or a red wine-hydrogen peroxide mixture as an extended rinse for the mouth. Please see additional cautionary notes for the use of hydrogen peroxide within this report. Full and entire credit for the discovery of this method is to be given to Dr. Gwen Scott, N.D. and the public has a call to be grateful for the many unselfish contributions that she has made to the understanding of the "Morgellons" issue (please also see [A Natural Medicine Approach](#) on this site).

The use of the term "Morgellons" is a dubious approach as the pathogenic forms first discovered within a purported "Morgellons" subject are showing themselves to exist in equal form within the general public. To date, no human being is excluded from the findings of recent research through this site; hopefully exceptions to this case will soon be found. Thus far, fourteen individuals across numerous state lines have subjected themselves to the test method that is depicted on this paper. All fourteen produce and manifest the same physical forms through the gums of the mouth and only the amount of the material produced varies from individual to individual. The manifestation of skin conditions characteristic of the so-called "Morgellons" condition is not required to produce the result shown.

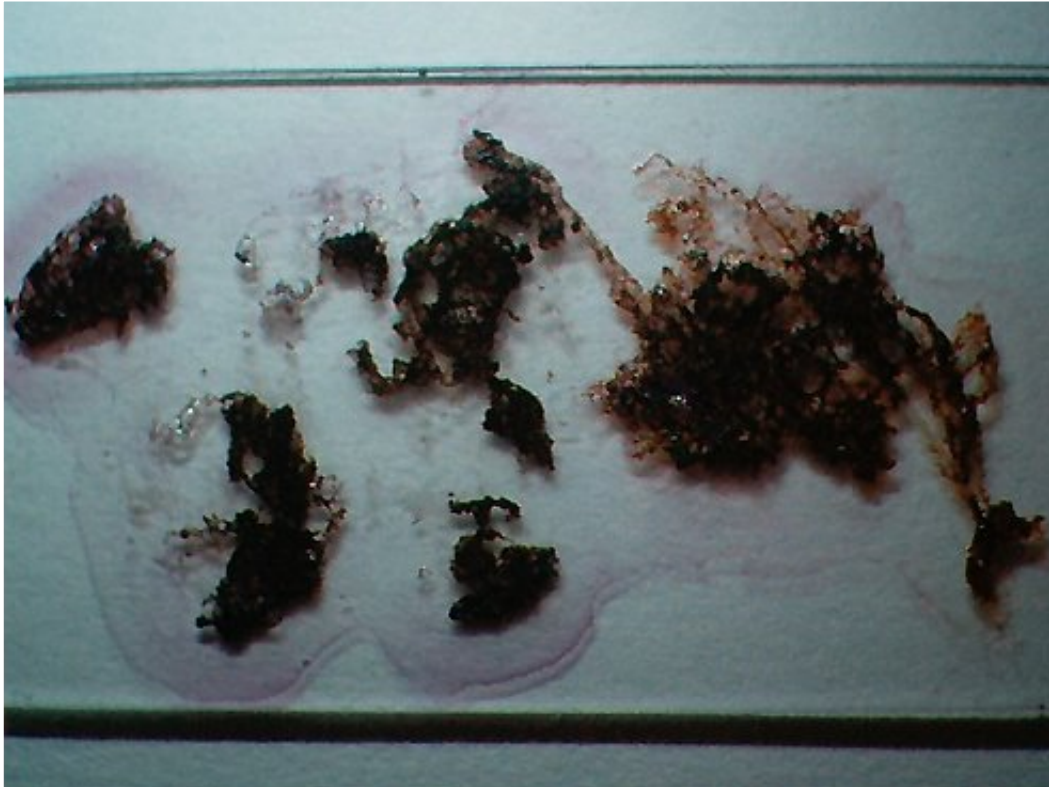
I state clearly again that the pathogenic forms under investigation are repeatedly showing up in the general population, regardless of whether certain "skin anomalies" are present or not. The pathogenic forms were, however, first discovered as a result of examination of these same skin anomalies. The segregation of only certain individuals as having the "Morgellons" condition is completely and totally false; the general population is involved whether they would like to know of it or not. The pathogens found have now been discovered repeatedly across all major body systems and functions, including skin, blood, hair, saliva, dental(gum), digestive, ear and urinary samples.



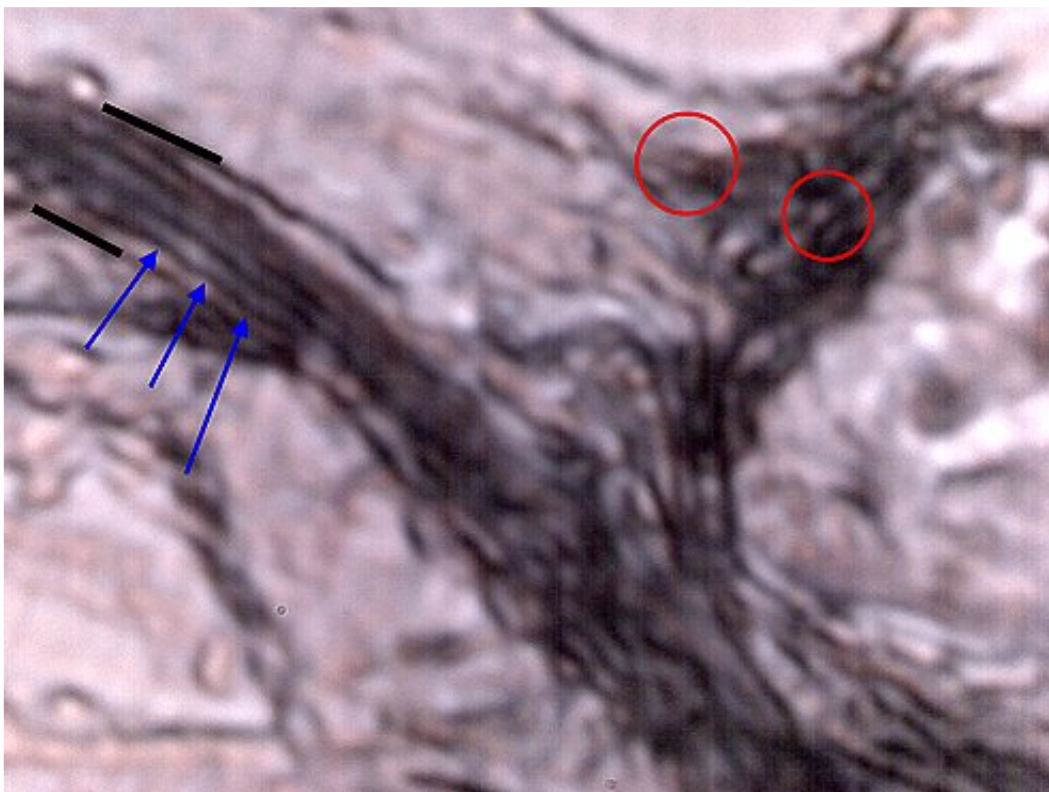
Gum-dental samples collected after extended wine-hydrogen peroxide mixture rinses of the mouth (e.g., 5 minutes each) and placed upon a glass slide for observation. Mouth brushed and cleaned to best degree possible prior to the test. Material emanates from the gums of the mouth; this individual produces a greater amount of material relative to other individuals.

Foam appearance results from the peroxide. Core material is composed essentially of the four pathogenic forms that have been extensively described on this site(encasing filament, sub-micron filament network, Chlamydia-like structures and the "hybrid form"). Samples have repeatedly observed at extreme visible microscopic examination, i.e., 7000x and they are generally consistent between various samples. One mixture that is under trial is 1/3 3% hydrogen-peroxide mixed with 2/3 dark red wine (e.g., merlot). Burgundy color results from stain of red wine. Another alternative under investigation is to limit the exposure to hydrogen peroxide by swabbing the teeth with peroxide prior to an extended rinse with red wine.

Hydrogen peroxide is NOT to be taken internally. Sensitivity and reactions to peroxide may be of concern and an issue to consider. NO THERAPY OF ANY KIND IS BEING RECOMMENDED WITHIN THIS REPORT; OBSERVATIONAL ANALYSIS ONLY IS BEING PROVIDED. Identical pathogenic forms have now been found across most body systems and functions. The rinse test has in some cases been ongoing for 1-2 months; there continues to production of some material in most every case. Microscopic examination will be required for any final determination. On occasions, the test has been conducted several times in a row (e.g., 30-45 minute session of approx. 5 minutes each) with no cessation of material to date, although the amount appears to eventually decrease. It appears that the production of material can be correlated directly with the amount of time devoted to testing. The presence of the material also appears to be associated with a ear-blockage condition in one case. Not all individuals produce this amount of material and the sample may need to be examined very closely to determine if it exists; it usually appears as fibrous or stringy if present. The individual providing this sample does not demonstrate any outwardly visible "Morgellons" symptoms.



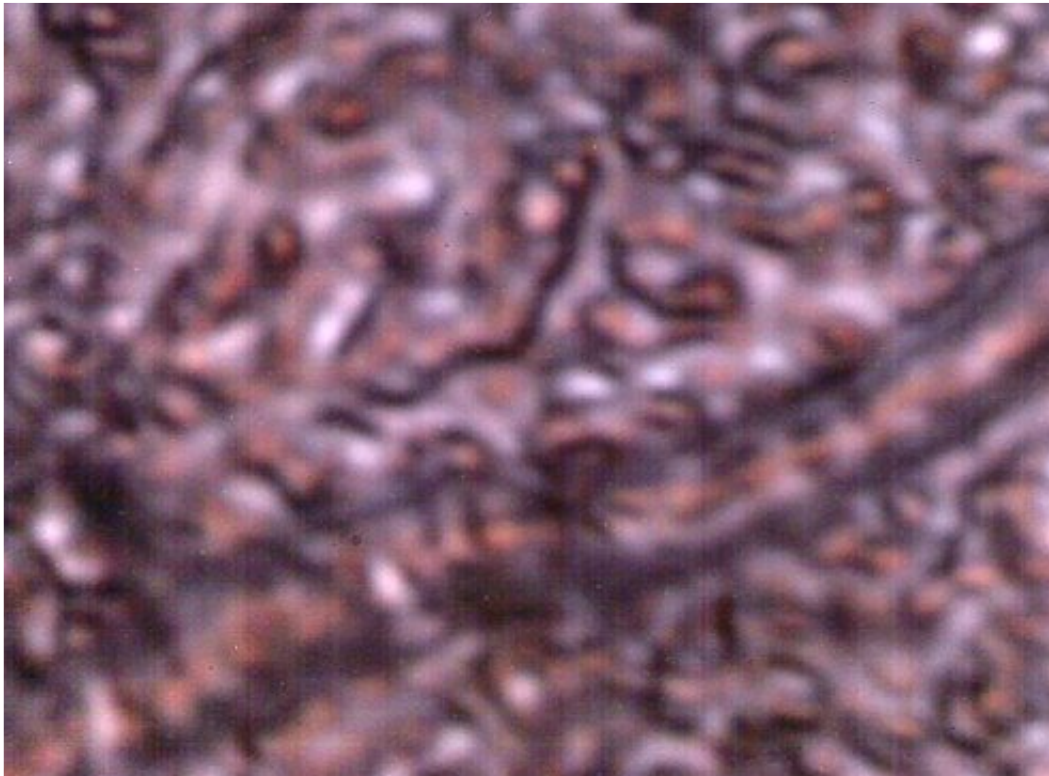
A similar gum-dental sample after drying and evaporation of the wine-peroxide mixture. Solid materials remain which form the basis of one of many recent analyses through this site.



One portion of the sample above observed at extreme visible magnification under the microscope. Dental-gum expelled sample. Sample extracted with use of hydrogen peroxide-red wine mix.

(please refer to [Pathogens & the General Population](#))

Three pathogenic forms visible: bounding filament (black border),
sub-micron interior filament network (blue arrows) and Chlamydia-like organisms (red circles).
Magnification approx. 7000x.



Microscopic examination of another gum-dental sample expelled from a separate individual using the wine-peroxide mixture.

An encasing filament and the Chlamydia-like structures are visible. In this individual the hybrid form is more common within the bounding filament as opposed to the sub-micron filament network.
Magnification approx. 5000x.

This method described above is not provided as a therapy or diagnosis of any kind; the reaction is being described from an observational point of view. Individuals are to consult with their own health practitioner for their health needs.

This website exists on a month-to-month contract. The existence of this website is not guaranteed. There is no known independent off site copy of this website. The public should preserve, protect and distribute the information on this site to their own level of confidence and assurance. Additional revisions may follow. Please distribute this information as rapidly and widely as is possible.

Clifford E Carnicom
Mar 09 2008

Morgellons - Introductory Remarks with Dr. Gwen Scott

Mar 21, 2008

ARCHIVE WEBCASTS:

“Morgellons” – Introductory Remarks

by

Clifford E Carnicom & Gwen Scott N.D.

Recorded March 21, 2008

[Download Version \(35MB\)](#)

Windows Media Format

Hit the Play Button to Start

(Length: 30 minutes)

Apr

Morgellons - 2nd Session - with Dr. Gwen Scott

Apr 11, 2008

ARCHIVE WEBCASTS:

“Morgellons” – 2nd Session

by

Clifford E Carnicom & Gwen Scott N.D.

Recorded April 11, 2008

[Download Version \(31MB\)](#)

Windows Media Format

Hit the Play Button to Start

(Length: 30 minutes)

AEROSOL ANOMALIES

Apr 17, 2008

“AEROSOL ANOMALIES”

Posted on Behalf of the Submitters

by

Clifford E Carnicom

Apr 17 2008

During the past month, two individuals have submitted a series of photographs to me that depict unusual airborne forms. To my knowledge, neither of these individuals is in contact with the other. The photographs are stated to be original. In both cases, the photos shown here are reported to have taken place in the midst of heavy aerosol operations over the respective geographic regions.

The photos in both cases show unusual ring-shaped or disc-like objects. The photos in one case are quite clear and remarkable. The fact that the second set was even captured is also fortunate. A statement from the photographer in each case will follow the images that have been submitted. These photographs raise several questions about at least some aspects of the aerosol operations and they appear to defy any conventional perception of aircraft. The accompanying “emission trail” with the ring like structure of the first set is especially curious. My appreciation is extended to both of the individuals that have offered their images to the public in the quest to further understand the nature of the aerosol operations.

SET ONE:



Magnified Section of Ring Like Structure

in conjunction with “emissions” of an aerosol operation.



Second Image of Ring Like Structure (highly magnified)
in conjunction with “emissions” of an aerosol operation.



Above photo(1of2) reduced in scale to show greater perspective on “craft”.



Above photo(2of2) reduced in scale to show greater perspective on "craft".

Statement by the observer:

"I saw this chemtrail forming to the west of Vail, Colorado on March 7, 2008 at 5:23PM. As I zoomed in full with a 70 to 300 lens on my D200 Nikon, there appeared to be no plane in front of the chemtrail – like it was forming out of thin air. After shooting several shots, there was another plane-less chemtrail rising to the west just before sunset. It was spooky. When I downloaded the pictures, there was a halo shape at the front of the chemtrail in some of the images and absolutely nothing visible in others. The Air Force has had stealth aircraft that are invisible to radar for quite some time. Apparently they now also have aircraft that are invisible to cameras as well. Why would stealth aircraft be flying missions over ski country? I became chemtrail aware during my investigation into the true story of the 911 attacks. But it did not hit home until November 18, 2007 when I documented the first saturation mission over Vail. That Sunday started mostly sunny. Then one jet flew over high and fast and left a huge expanding plume. It was followed by jets flying from all points of the compass. Inside of three hours, the sky was covered in a gray soup of converging chemtrails. The sun was partially blocked out. Then the planes vanished and not one was seen the rest of the day. After documenting a saturation mission over Crested Butte on December 13, 2007 where the sun was completely blocked out in three hours – there was no doubt left that something sinister was being perpetrated by the Air Force in Colorado. I've watched jets leaving no contrail at all fly towards a cloud and turn on the chemtrail upon entering the cloud and exit the cloud leaving none. I've photographed jets at similar altitude leaving no visible exhaust trails flying near jets leaving huge chemtrails. The next day after saturation missions, I've seen a return to normal jet traffic and normal vanishing contrails. The denial from people that say this is all normal don't remember what it was like in the west before the late 90s. The deep blue sky without a cloud that lasted three weeks straight on a regular basis during summers never happens now. When I flew across the country last time, I didn't see the ground once from Denver to Boston. The clouds looked weird and fibrous; unnatural. I have images that show clouds of green, purple and rust colors. That simply can't be water or you would see the rainbow colors. After 25 years in Colorado, I have no memory of the chemical colors I now see regularly in clouds. I also have no memory of the strange chemical

halos around the sun. I certainly have no memory of planes leaving trails in a grid that block out the sun in three hours. The time lapses I have of this are indisputable evidence to me. Most people I show my evidence to think I have a point that something is terribly wrong with these pictures. Other people roll their eyes and think of me as a paranoid delusionist. I see that as a huge obstacle to stopping this madness. People simply don't want to believe the truth that the government of the United States would do anything to harm them. You can show them the documents released through the freedom of information act about the mind control experiments, the intentional infection of black men with venereal disease, lining up soldiers in front of a nuclear blast wave and they still believe this same government wouldn't pollute the Earth for all time to gain a military advantage. I'm not sure how to reach these people. Preaching to the quire will get us no where. What will convince these people? Perhaps nothing will until they get Morgellons disease."

SET TWO:




Second anomalous disk-ring like structure reported in combination with heavy aerosol operations. Separate geographic region and time from first set.



Reduced scale on second disk-ring like structure reported in association with heavy aerosol operations over area.

Statement from photographer is to follow.



Second photograph by second photographer presented for informational purposes only.

Disk object barely visible.

Please see text description below (arrow added by CEC for clarification).

Statement by the observer:

As discussed please find attached the two photos of the unidentified flying disc I captured. The first one attached is much clearer and was taken on Sunday March 23, 2008. It was observed out of peripheral vision, and barely captured it although it was on a straight horizontal flight path but fast, faster than the aircrafts in the airspace at the time precise time!!! without the UV filtering sunglasses I normally wear but didn't that day. It was smack dab in the middle of the airspace precisely during the time of heavy activity via the daily observed same aviation assault team. [assault team described here: <http://dayspringgatheringscircle.org/blog/?p=881>]

The second photo was taken TODAY [Apr 14 2008 Ed. Note-CEC], is the same unidentified flying disc, but today's story is quite different. I was wearing my UV filtering sunglasses and caught the beginning erratic activity out of the peripheral vision once again as we were filming all the heavy activity of the daily observed same aviation assault time and out of the corner of my eye I caught an erratic movement, then in a split second going straight VERTICAL and FAST, as soon as I dropped my UV filtering Sunglasses it vanished right were it was as I had my glasses on, flipped my glasses back on and it caught in the same airspace region precisely where I couldn't see it seconds before [light reflection? light bending?], anyways, this disc did a figure 8, went left and went right, banked left 90 degrees and then shot straight up vertical into the cloud cover ahead. This all happened in split seconds, and with a wing and a prayer I just flicked on auto and took the shot because the disc was rising straight vertical so fast I thought it would be gone before the shutter could capture it. You will notice that the disc on the second photo almost out of the frame, top of the photo, on its vertical straight rise, whereas on the 1st photo, it was on a horizontal flight path, course I didn't think to track it on the first photo, like I was able to track and observe it the second time. This thing looked exactly like it was remote controlled as fast it did a figure 8 then went left ,right and vertical. By the way, the same aircraft were in the same airspace both times, what I call the worker bees. All in all, I have now observed this disc 4 times, and at all times directly in the middle of heavy aerial activity.

Editor's Notes:[CEC]

1. The photographs are stated to have been taken in North Carolina.
2. The photographs from set two are the protected private work property of DaySpring Gatherings by Gabriel Paul. THE IMAGES FROM SET TWO ARE NOT TO BE COPIED SEPARATELY FROM THIS SITE and they have been posted solely with the permission of the author.
3. An assessment is provided by the second photographer that the craft is NOT likely from "other planets", but may be "human made as a remotely controlled 1)discharge unit, 2) atmospheric testing apparatus, 3)surveillance eye, 4)combination of all the above and more to toss into the puzzle."

Jun

Instructions for Boosting Your Microscope's Power to Examine Your Own Samples

Jun 24, 2008

Instructions for Boosting Your Microscope's Power to Examine Your Own Samples

Editor's Note: This page has been prepared by a citizen for the benefit of the public and it is subject to further editing. The purpose is to introduce the readership to the general technology being used. Magnifications of approximately 8000x and the detection of biological components to approximately 0.2-0.3 microns have been achieved with the general methods described on this page. My appreciation is extended to the author of this paper for his extended efforts and for the service that has been provided to the public.

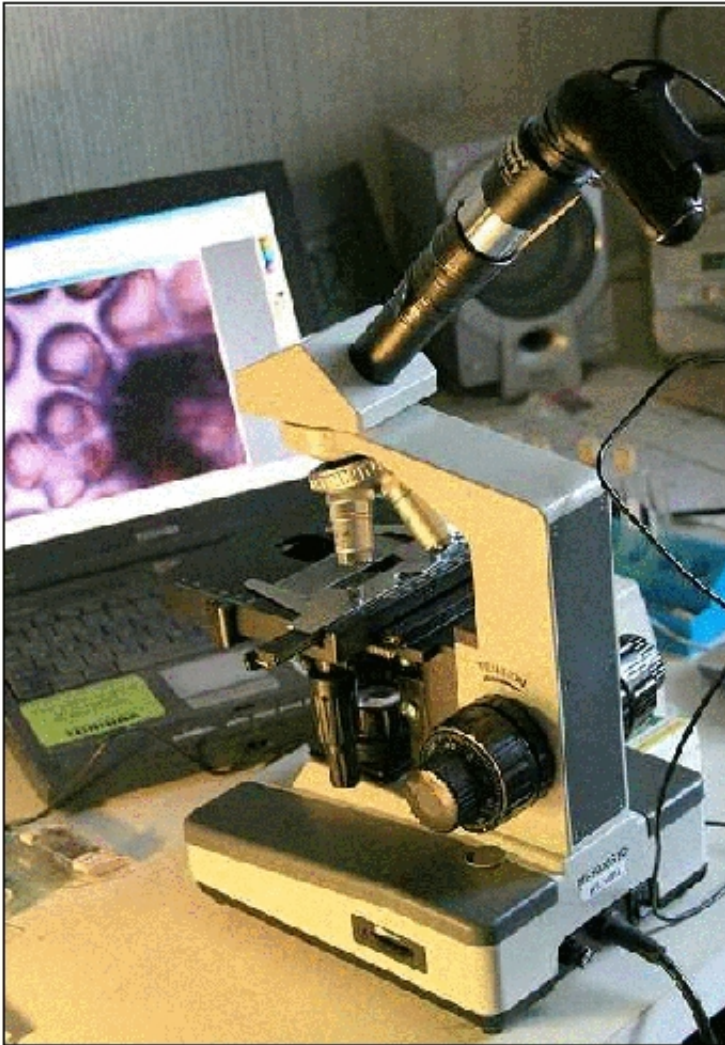CE Carnicom Jun 24 2008

Edited Sep 08 2008

Edited Nov 17 2008

Edited Aug 23 2009

This page introduces a modification that can produce up to 4,000x magnification with an ordinary digital microscope and a webcam's CCD chip.



Analog microscope adapted with a webcam's CCD chip (plus, in this case, a telescope's 'Barlow' lens).

THE CHALLENGE: VERIFYING THE FINDINGS

If Mr. Carnicom's findings of blood and other abnormalities are shown to be replicable by any interested person with a microscope, it would indicate that widespread blood infection and air contamination by unknown agents are most likely a reality. If such blood and air abnormalities are the reality, then having as many independent verifications as possible of the facts involved would be a very good way to convince the general public of that reality. Once that reality is generally accepted, the urgent priority hopefully would then become determining how we can best engage with that reality as quickly, effectively, and as healthfully as possible.

Thus it is now essential to have as many independent verifications of the findings as soon as possible and to have the evidence of those verifications posted on the Web and shared widely with these ends in mind.

THE SOLUTION: BOOSTING YOUR MICROSCOPE'S POWER

The magnification needed to view the abnormalities in blood and other samples, however, is high to very

high—from 1,000 to 7,000 times (x)—with powers over 1,500x usually being too high for normal unmodified optical microscopes. But due to the ingenuity of some amateur astronomers and

Mr. Carnicom, there now exist at least two relatively simple and inexpensive do-it-yourself methods by which interested members of the public can modify their own microscopes and directly image their own samples to 4,000x and even higher. Both methods adapt a simple web camera's 'charge-coupled device' (CCD) chip to microphotography—replacing the eyepiece of the microscope with the webcam's CCD sensor is the key. You will be replacing the webcam lens with your microscope lens.

Besides using a CCD chip, the more involved method—which gives the highest magnification power—also involves adapting a telescope's 'Barlow' lens to the microscope, and is not covered by this how-to document.

The simpler method—which, although it gives less magnification power, still magnifies samples much more than do unadapted microscopes—uses only the CCD chip and will be the focus of this paper. Below are the step-by-step instructions needed for this simpler method, which provides a maximum magnification of approximately 4,000x and can be built in one afternoon for as little as \$35.

(PLEASE NOTE: Opening the webcam case will void the webcam's warranty. Also, implementing the following modifications and procedures are done at your own risk, and so you will be solely responsible for any damages that might occur to your webcam.)

WARNING: For your own safety, any attempts to replicate the micrography techniques mentioned on this website must include observing samples by way of one's computer's monitor only and NOT directly through one's microscope. ***This is absolutely mandatory when working with any LASER light, which can cause serious eye injury and blindness. Serious precautions must always be taken when working with any operating LASER.***

MATERIALS

The homemade CCD imager is based on the Logitech QuickCam (two versions shown below) from Connectix (www.logitech.com). These can often be purchased affordably on eBay.com



Parts needed:

- One QuickCam webcam (any model)
- One black plastic 35mm film canister (Kodak cans recommended for their protruding 'lip')
- Silicone adhesive

Tools needed:

- Digital microscope (best quality possible)*
- Personal computer + monitor
- QuickCam imaging software
- Small regular-head screwdriver
- Small Phillips-head screwdriver
- Small Allen-head screwdriver
- Small paper clip (or small jeweler's screwdriver)
- Fine-tooth coping saw or hacksaw
- Grounding strap

* Mr. Carnicom states that the best microscope he has is called the "Ultimate Home Microscope" (also

known as the "Ultimate Digital Microscope") from Home Science Tools (www.hometrainingtools.com).

OBJECTIVE 1: Open Up the Webcam

a) Remember to not leave the webcam interior open to the air for too long (as dust could get on the CCD chip), so have your film-canister eyepiece adapter ready. Before opening up the webcam and in preparation for mounting, take the plastic (Kodak) film canister, remove its cap, and cut out the bottom with either a fine-tooth coping saw or a hacksaw. Be sure to remove all debris and dust from it and the immediate work area. Extreme cleanliness is vital, as even a tiny dust/debris particle on the CCD chip will interfere with your microscope imaging later.

b) Look at the QuickCam's ball-shaped housing where the two halves meet and find a tiny hole about the diameter of a paper-clip wire. (NOTE: Depending on the model, this may be hidden behind a small sticker, which can be easily peeled back.)

c1) Insert the end of a small jeweler's screwdriver or a paper-clip wire into the hole and gently press it in until you feel a snap. You have just unlocked one of the three retaining clips that hold the ball together.



c2) Alternatively, if there is a screw visible, insert the appropriate small screwdriver into the hole and unscrew it.

d) Carefully pry the ball apart with a small regular-head screwdriver, taking EXTREME care not to damage or dirty the QuickCam's internal components.

OBJECTIVE 2: Alter the Webcam for Microscope Use

For the next several steps, you should be properly grounded to prevent the buildup of static electricity, which can damage the camera's sensitive electronics. (Most computer supply stores sell tiny "grounding straps" with which one can connect one's body to a plumbing pipe or some other grounded structure prior to doing the following steps.)


In addition, ***it is extremely important to keep the CCD chip clean! Even a tiny fleck of dust on the CCD chip can interfere with later imaging.***

a) Inside the QuickCam, you will find several pieces, including the lens, lens mounting, a metal spacer adjacent to the lens, and a metal counterweight that doubles as a tri-pod. Remove the lens by simply unscrewing it.




b) If there is an LED visible in the webcam, tape a small piece of black tape over it to prevent excess light interference when the webcam is turned on.

c) Identify the CCD chip and the lens mounting as two separate objects within the webcam. REMOVE THE LENS FROM THE LENS MOUNTING BUT LEAVE THE ACTUAL LENS MOUNTING IN PLACE. THE REMOVAL OF THE WEBCAM LENS IS A CRITICAL STEP. THE CCD WILL BE EXPOSED TO THE AIR WHEN THE MODIFICATION IS COMPLETE AND YOU MUST KEEP THE CCD CHIP AS CLEAN AS POSSIBLE FROM THIS POINT FORWARD. ANY DUST OR DIRT OF ANY KIND ON THE CCD CHIP WILL INTERFERE SIGNIFICANTLY WITH THE RESULTS THAT WILL BE ATTAINED.




QuickCam circuit board with lens mount still attached.



QuickCam circuit board with lens mount removed and CCD chip exposed.

- d) Reassemble the webcam's body, now minus the lens (and possibly the lens mounting).
- e) With the silicone adhesive, CAREFULLY glue the top of the film canister (now with its bottom cut off) directly over the top of the hole in the webcam where the lens once was. The CCD light-sensing chip remains in the webcam's circuit board in its original state and form.

Regardless of which method is used, after gluing on the film canister, wrap one-inch masking tape around the microscope's trinocular port or around the second eyepiece tube on a binocular viewing head so that the proper diameter makes a snug fit of the film canister over the tape.



Here is how one possible end result will look.
In this case, the webcam body has been reassembled and the film canister glued onto it.

OBJECTIVE 3: Connect the Webcam to the Computer and Microscope

- a) Depending on your computer model, either attach the QuickCam to the keyboard/mouse-jack of your computer or plug it directly into your computer's USB port.
- b) Remove the eyepiece from your microscope.
- c) Insert the film canister tube—with part of the QuickCam now attached—into the microscope's eyepiece holder.

OBJECTIVE 4: Test the Imaging Ability

- a) If you have not already done so, install the webcam's imaging software before using the camera, following the instructions that came with it. Once the webcam software is installed, go to the Logitech downloads web page at http://www.logitech.com/index.cfm/support_downloads/downloads/&cl=us,en) and download the latest drivers and software.
- b) Focus the microscope onto a test target and look for its image to appear on your computer monitor. The webcam will produce real-time images, meaning that you can adjust the 'aim' of your microscope and see the results on your screen at the same time. Adjust the focus control until the image is at its sharpest.
- c) If the image is not evenly sharp across the field, that means the CCD in the QuickCam housing is tilted a little. Open up the camera again and shift one side of the CCD chip to even things out. Then put it back onto the eyepiece holder and try the test target again.
- d) To take a photograph with the imager, simply click the QuickCam's program screen with your computer's mouse cursor. When photos are taken, save them so you can adjust their quality with QuickCam's software or another imaging software program, such as Adobe Photoshop.

You can also use the webcam's digital zoom feature to increase image magnification, if necessary. The webcam's software allows you to increase the image magnification by 2x in 10 increments. There will be a loss of resolution, since the webcam's software records fewer pixels and uses interpolation algorithms.

OBJECTIVE 5: Obtain Samples to Examine

Before going straight to blood samples, you'll probably want to start with somewhat simpler things.

Any objects examined must be extremely thin and only about one cell width in thickness. Some examples include:

- Cheek cells swabbed from one's mouth with a toothpick.
- Onion skin. Perfect practice material; an onion skin is one cell in width and has large, easy-to-see cells. It also allows light through, is thin, and is easy acquire.
- Epsom salts can be dissolved in water and then dried, resulting in interesting crystals to examine.
- Relevant samples can include blood, the material resulting from swishing various liquids in the

mouth, and airborne samples, among others.

- According to Mr. Carnicom, not every blood cell seems to be infected, at least in healthy people. But usually every microscope slide blood sample will contain some cells with signs of it.

If you aren't already familiar with using a microscope and basic microscope techniques, Clifford recommends *The Microscope Book* by Shar Levine.

Amazon.com link:

http://www.amazon.com/dp/080694899X/ref=asc_df_080694899X4030504?smid=A1505AP5HMQ6QA&tag=shopz0d-20&ascsubtag=shopzilla_mp_1573-20;14499677614663721771810060301008005&linkCode=df0&creative=395105&creativeASIN=080694899X

A couple of the larger science-oriented suppliers for microscope supplies—including slides, etc.:

- **Science Kit** at <http://sciencekit.com/>
- **Edmund Scientific** at <http://scientificsonline.com/>

OBJECTIVE 6: Capture High Quality Images of Samples

Tips

- Refer to a good introduction to microscope technique, such as the previously mentioned *The Microscope Book* by Levine.
- Samples should be adjustable on the microscope's stage.
- It's important to remember that light has to get through the sample in order to be able to really see it. The more transparent a sample is, the more can be seen. The higher the magnification power, the more light is required.
- You'll need very fine focusing ability at these magnification levels, one reason why acquiring the best microscope you can is important.
- Experiment with imaging often.
- Spend some time in observing and become familiar with what you're looking at.
- Proficiency comes over time, so having patience is also important.

Again, the more involved method—adapting a telescope's 'Barlow' lens to the microscope, in addition to using a CCD chip—gives the highest magnification power. Perhaps others will undertake another instruction set for that project.

OBJECTIVE 7: Post and Forward Image Results

a) Once you have imaged and photographed blood, air, and/or mouth samples, you can forward the images with relevant commentary to Mr. Carnicom at info@carnicominstitute.org.

He will consider post high quality photos of interest that are sent to him on his website:

<http://www.carnicom.com/contrails.htm>

b) Independent verifiers are also encouraged to create websites of their own with which to present their results, along with a link to this page for instructions on how to replicate the procedures used that obtained those results.

OBJECTIVE 8: “Name the Demon” and Work Together

a) Although this subject of mass infection is (understandably) a difficult subject for many, “naming the demon”—concretely identifying a previously vague or nebulous threat—can be very useful in engaging difficult-to-handle issues. This is because it defines the threat, thus limiting its scope. In the case of Mr. Carnicom’s findings, “naming the demon” would mean perceiving and describing the actual physical parameters of the strange infection-causing agents and their activities. This knowledge will allow people to better understand the situation as it actually exists so that they can then engage with it effectively and ultimately overcome it.

b) This situation also might have a true ‘silver lining’ if it prods us to find effective means by which we can work well together for the good of all of us, in spite of different outlooks we might have on other matters. If Mr. Carnicom’s findings are fact, working well together may be our only way through.

Jul CULTURE BREAKTHROUGH(?)

Jul 12, 2008

CULTURE BREAKTHROUGH(?)

Clifford E Carnicom

Jul 12 2008

I have no medical expertise and I claim none. I am not offering any medical advice or diagnosis with the presentation of this information. I am acting solely as an independent researcher providing the results of extended observation and analysis of unusual biological conditions that are evident. This paper is, nevertheless, provocative in its intent.

Work has been conducted over the past one to two months that appears to be important and it may have significant impact. It appears as though a primary pathogenic form under evaluation that is associated with the so-called "Morgellons" condition may have been successfully cultured. If this proves to be the case, it offers the potential to begin very serious research on the methods to control, inhibit, reduce or eliminate the pathogenic forms within the human body. My opportunities to conduct such research are quite limited due to additional demands, and this information is offered for the public benefit so that this process can begin without delay. I will continue to do what I can. Unknown pathogens are difficult to identify, treat and remove if they exist only within the body; there is tremendous benefit if such pathogens can be grown or developed in a culture medium under controlled conditions. This report may offer a pathway to that process.

There can be no excuse at this point by anyone for the failure to conduct the necessary research that this report prompts. The responsibility for this action and any potential progress from it now rests with each of us.

Before continuing, let us briefly summarize salient findings by this researcher over the past couple of years on the "Morgellons" and Aerosol issues; the basis for these statements will be found within the body of research that exists on this site:

1. Five recurring, specific identical physical forms, all apparently of a pathogenic nature, are under continuous identification across the major systems of the human body. These include:

- a) A bounding, or encasing, filament form, approximately 12-20 microns in thickness.
- b) A sub-micron network of filaments within the bounding filament.
- c) Sub-micron oblate to spherical structures, potentially identifiable as a *Chlamydia pneumoniae* intracellular bacterial form.
- d) A "hybrid" form, usually of a ribbon-like nature. *Mycoplasma* (pleoforms) have been suggested as a topic for further research with this item.
- e) A "budding" form, which appears to emerge from the encasing filament, which further contains both items b and c on this list.

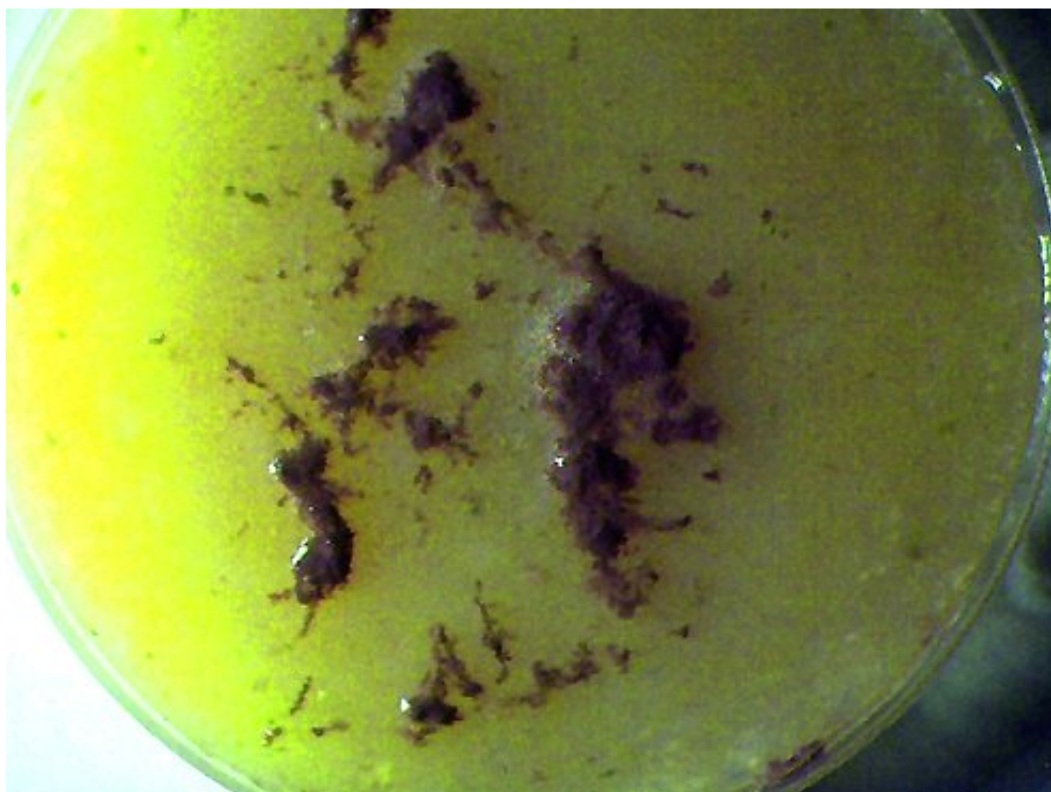2. Airborne filament environmental samples have been matched, to the degree possible with available equipment, with items a, b, and c of Item 1 on this list. The United States Environmental Protection Agency has refused to identify these airborne samples.

3. There has been no adequate or appropriate response, either by government, public or private resources to address the findings of Items 1 and 2 for approximately 10 years. The aerosol issue emerged as a controversial topic at approximately that same time, to be followed gradually over the following years with the emergence of the “Morgellons ” issue as another controversial topic. There is now sufficient evidence to consider the aerosol issue and the Morgellon’s issue as linked with the common denominators of physical form and delivery method. The EPA and the Center for Disease Control(CDC) are both culpable in this regard, along with other public service agencies.

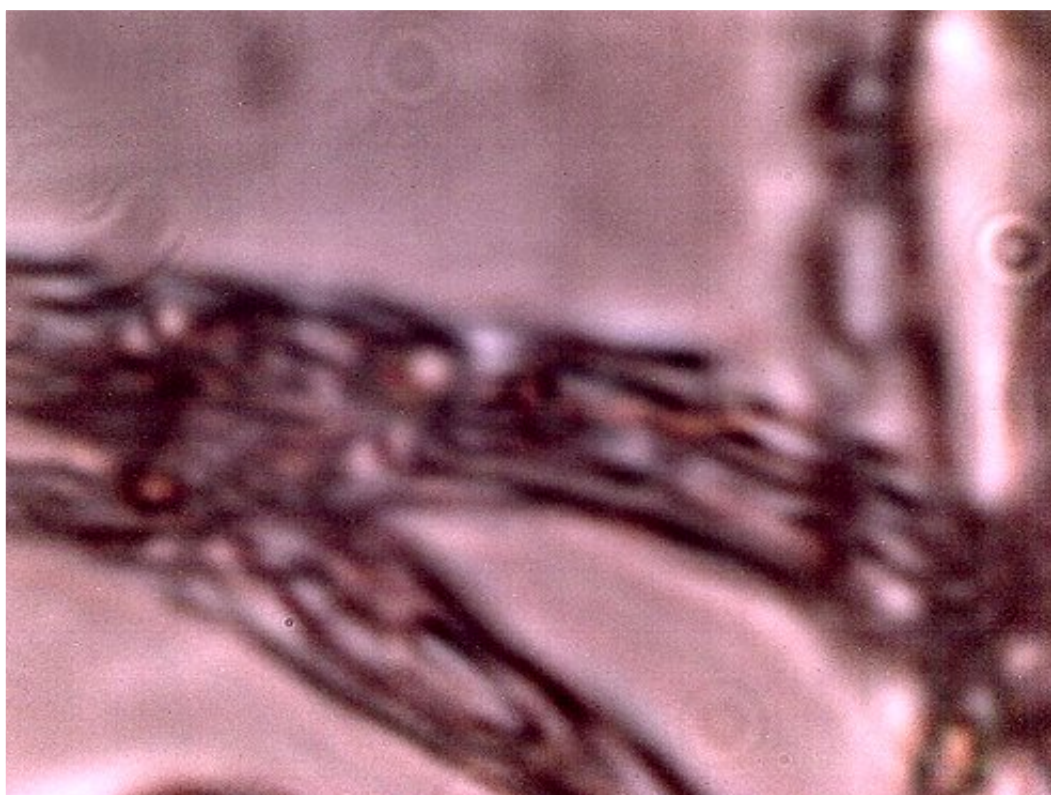4. The perception that the “Morgellon’s issue affects a only a relatively small group of individuals appears to be patently false, based upon the findings of this researcher. The skin symptoms (lesions, filaments, etc.) that are often called to attention as evidence of the condition appear to be only one restricted manifestation of more general conditions that appear to affect the entire population. Any individual that has provided biological samples(blood, dental) for observation demonstrates, to some degree, the pathogenic forms listed in Item 1. To date, no individual is exempt from this assessment. It is repeated that I am providing no medical diagnosis or determination with this statement; it is simply a point of fact of observation from this researcher.

5. The “dental test”, as reported on this site, continues to be a viable form of production of biological samples for further study. Such samples form the basis for this report. The filament dental form has been produced, thus far, by any and all individuals that have participated in the testing process. Some individuals have now been conducting this test for several months on a daily basis; there remains a continuous daily production of the filaments from the dental region of these individuals. There is no known exception to this statement as this time; if and when it is found it will be stated as such. Continuous gratitude and recognition is given to Gwen Scott, N.D. for the discovery and development of this test method; it exists as a crucial link in the subsequent work outlined in this report. The connections that have been made are a good example of how research often requires collaborative effort and resources, especially as the complexity of the situation increases. The aerosol and “Morgellons” issues have been deliberately constrained in progress due to their covert natures, and the work is years behind the state of healing that is eventually required.

6. The majority of the information on this page is available through various modifications that have been made to conventional microscopy equipment. The relatively high magnifications that have been achieved permit the detection of structure and form that would otherwise be invisible with conventional equipment. Cumulative image processing techniques have also been used to improve structure determination.



Original dental sample on agar sample. Magnification approx. 2x.



Original dental sample under the modified microscope.
Additional dental filament sample microphotographs

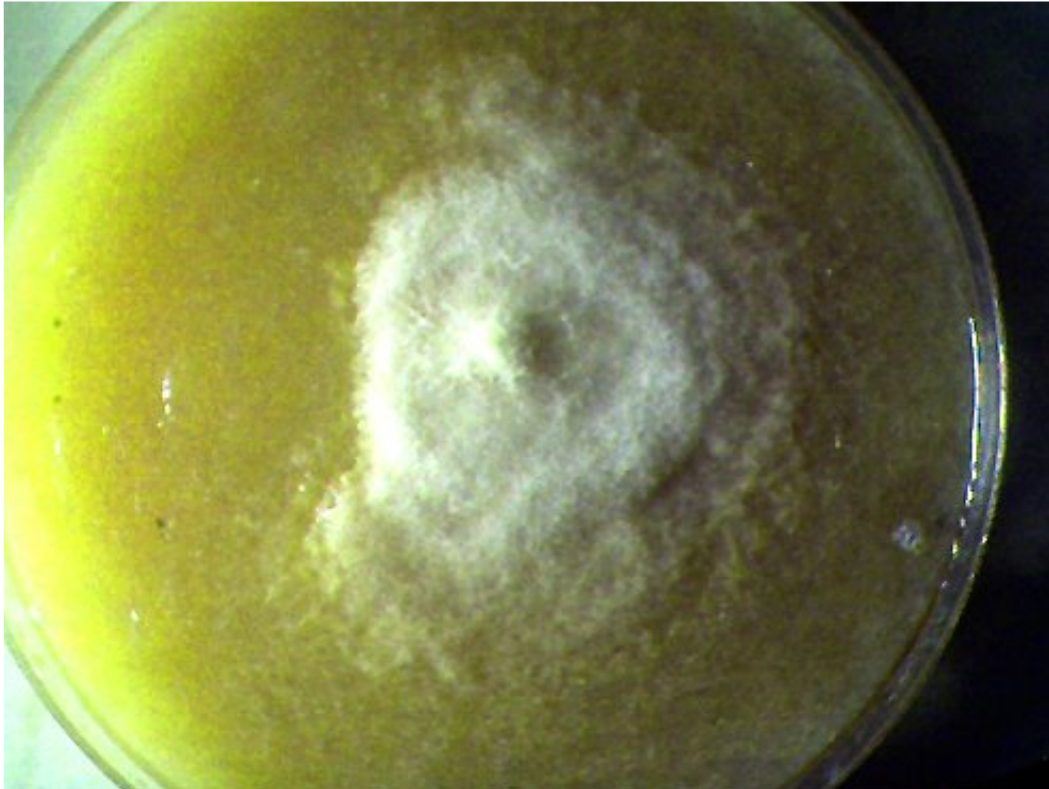
are available on this site; uniformity of structure, size and form is apparent. This is to be considered as the "*primary pathogenic form*" for the purposes of this report.. Magnification approx. 7000x.



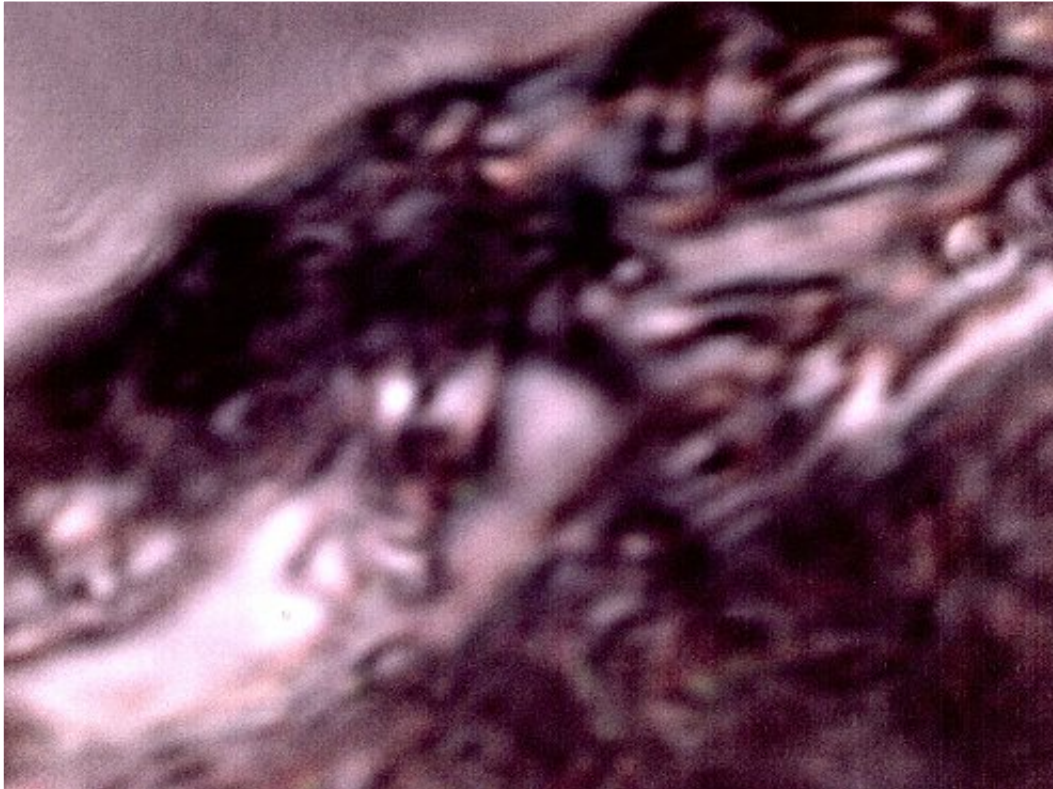Broad variety of fungal and bacterial forms that develop from the dental filament samples upon the agar culture medium. Time of development approximately 2 weeks. Magnification approx. 5x.



Close-up of pathogenic forms that appear on the filament dental samples on the agar culture medium after approximately two weeks of development.
The black circle encloses what appears to be a black mold species(*Stachybotrys*?)
Numerous species of fungi and bacteria develop from the dental samples on the agar medium.
The red circle encloses what appears to a separate genesis of the “*primary pathogenic form*”, i.e., the subject of this report. Magnification approx. 8x.

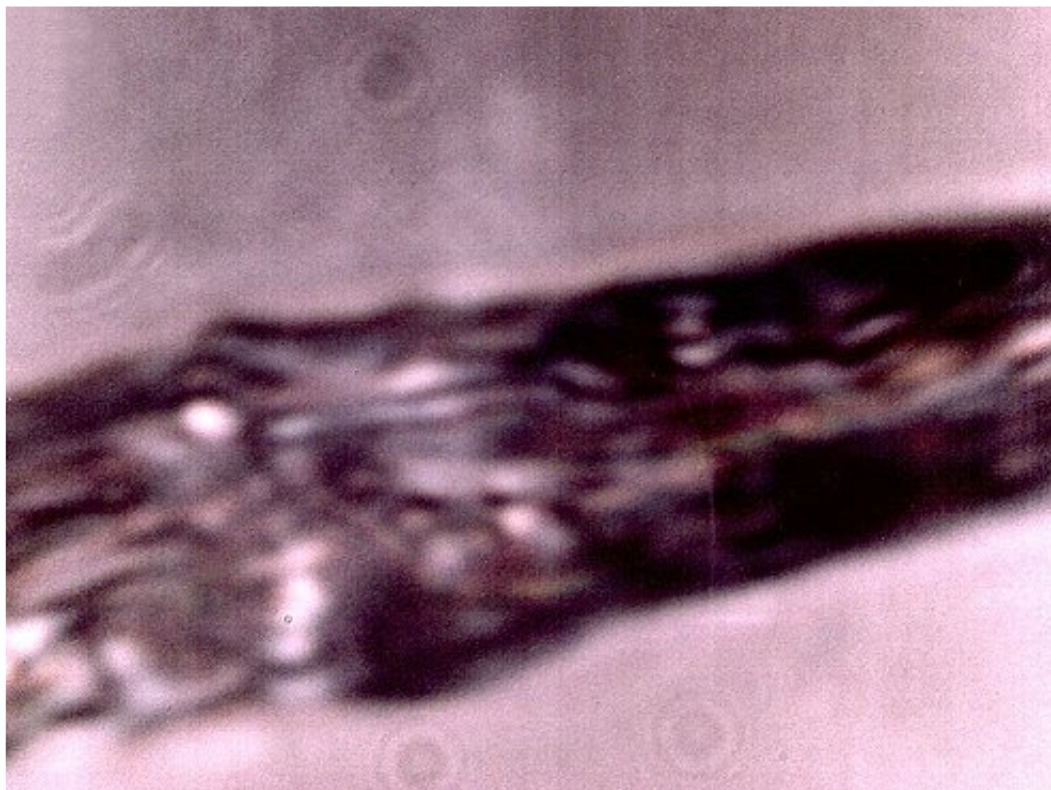

Isolated culture developed from the pathogens that have developed from the dental filament samples. This filament culture appears, under high magnification, to be absolutely equivalent to the “*primary pathogenic form*”, i.e, the dental filament form shown at the beginning of this report. This pathogen grows freely, broadly and quickly upon the agar culture medium used here (beef bouillon). The culture is easily propagated from one medium to another identical medium. It remains unclear at this point what specific conditions are required to create the culture form. Time of development approximately 1 1/2 weeks. No match found to an existing species at this time. Magnification approx. 2x.

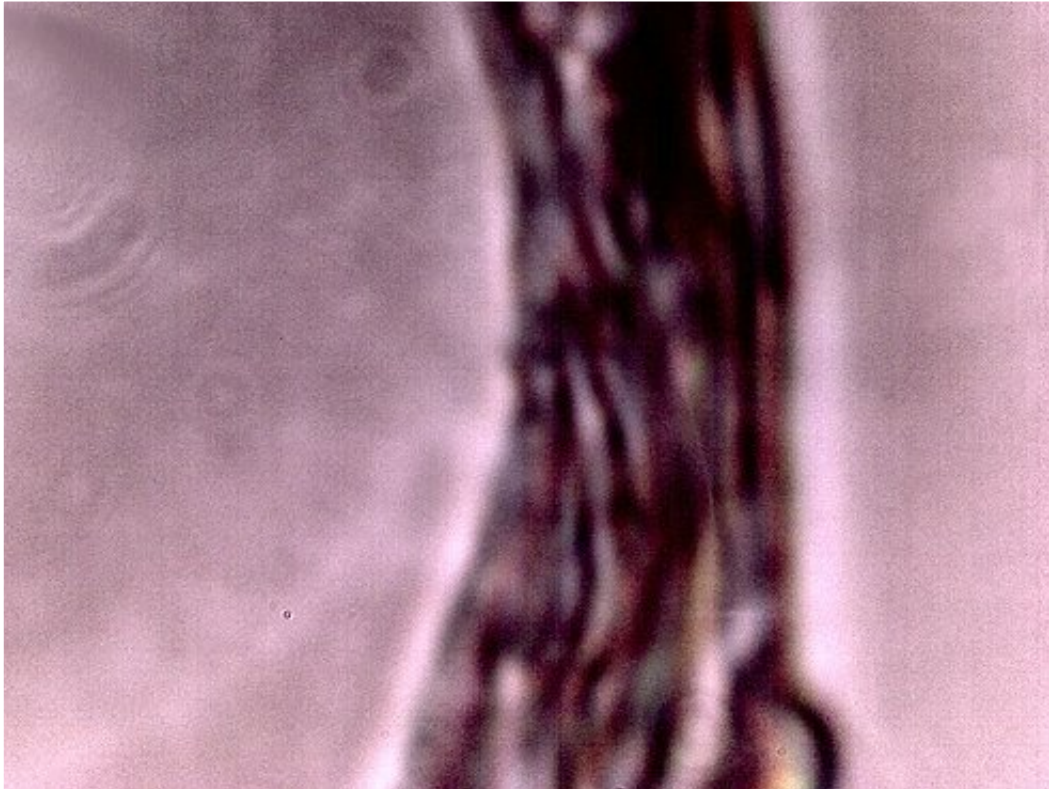


The filament from the agar culture medium growth under high magnification. It appears in all major respects(size, structure, form) to be identical to the “primary pathogenic form.” (i.e., the dental sample). Encasing filament, sub-micron filament network and sub-micron oblate/spherical structures are each identifiable within this microphotograph. This sample represents a *growth* on the culture medium and it is *not* the original dental sample. It appears that it develops from, and as a result of the dental filament sample.

If this proves to be the case, it represents a controlled development and duplication of the *primary pathogenic form*. Magnification approx. 7000x.

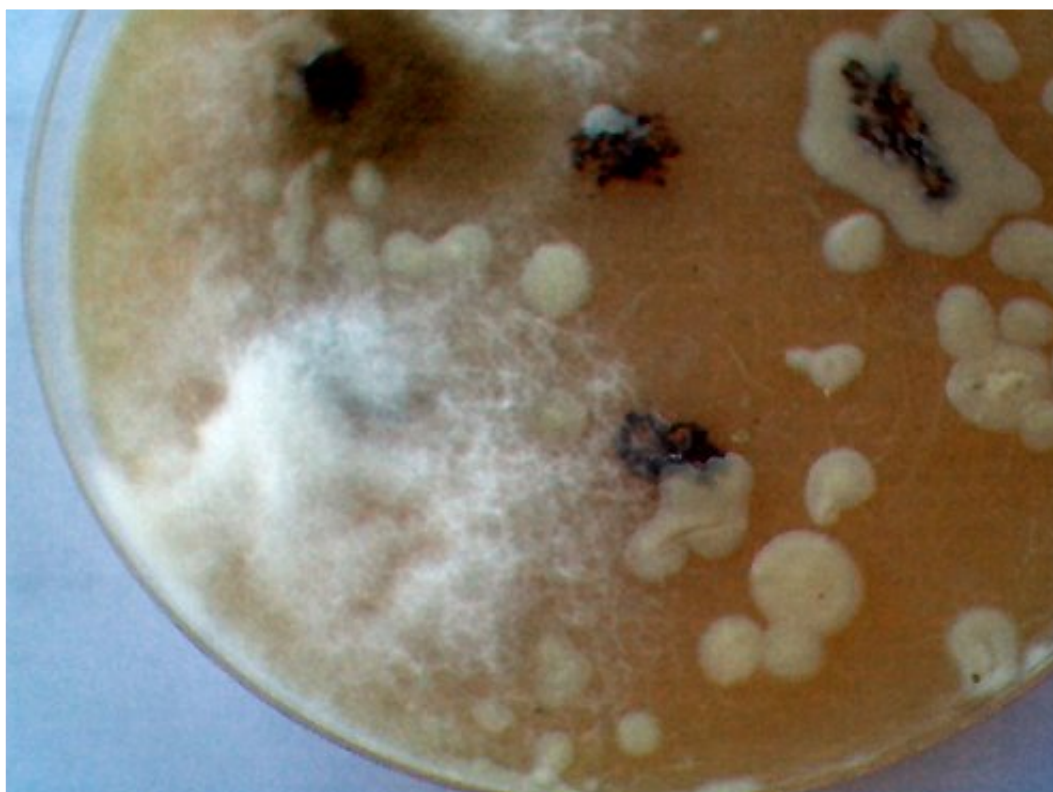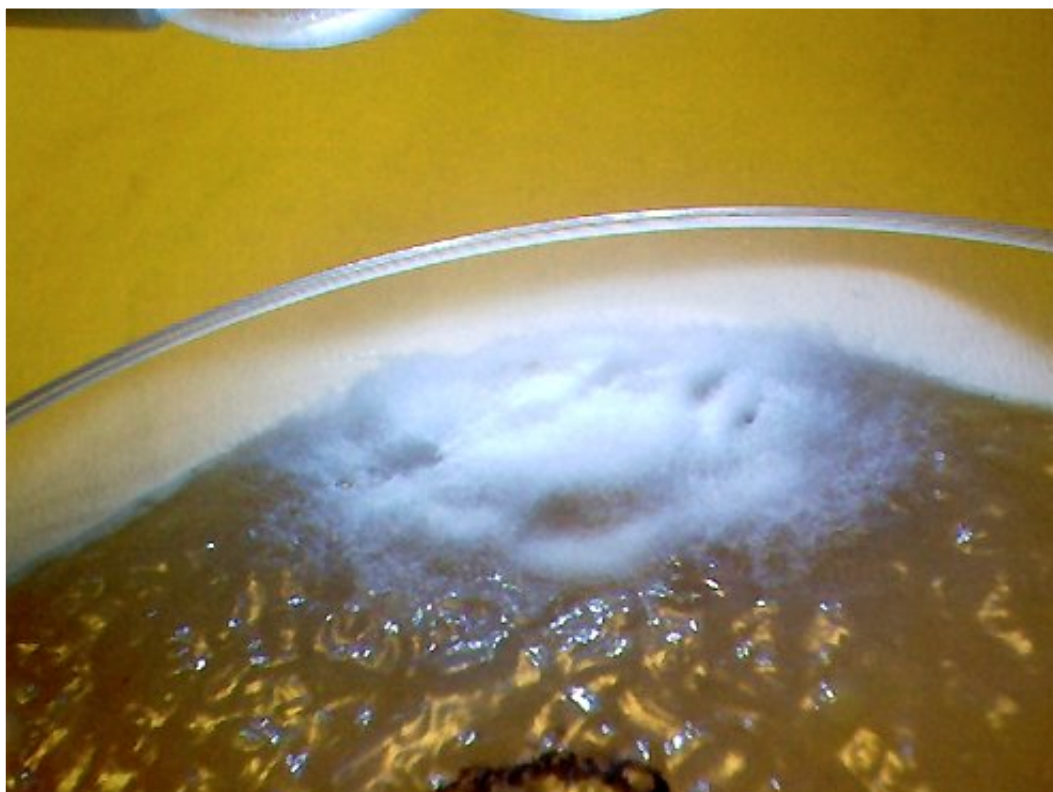


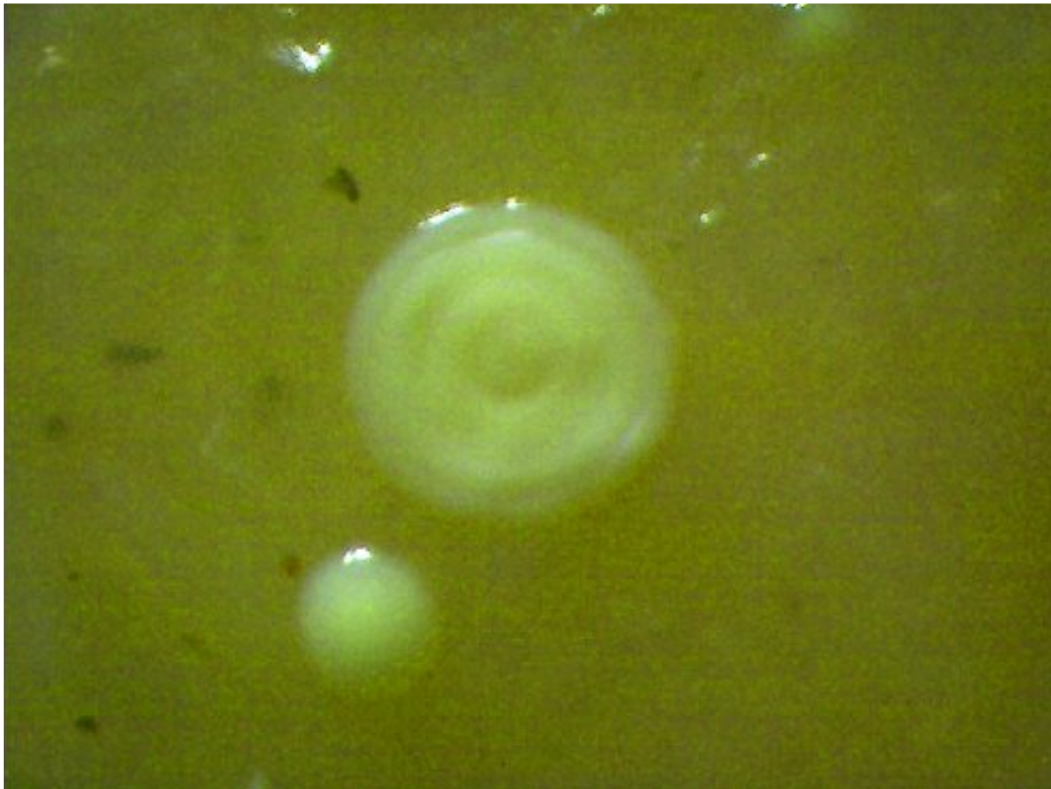
Additional microphotograph of the culture medium filament sample. Similarity, if not identity, to the primary pathogenic form is apparent. This pathogenic form has been identified in ALL humans that have subjected themselves to the dental testing process. Magnification approx. 7000x.



Additional microphotograph of the culture medium filament sample.
Similarity, if not identity, to the primary pathogenic form is apparent.
Magnification approx. 7000x.

Additional Photographs:
(to be captioned)





Aug
CULTURE WORK IS CONFIRMED

Aug 18, 2008

CULTURE WORK IS CONFIRMED**Clifford E Carnicom****Aug 18 2008**

I am not offering any medical advice or diagnosis with the presentation of this information. I am acting solely as an independent researcher providing the results of extended observation and analysis of unusual biological conditions that are evident.

A pathogenic form that appears to be directly associated with the so-called "Morgellon's" condition has now been successfully, repeatedly and positively cultured from numerous independent dental filament samples over a protracted period of time.

The initial work that establishes the background of this report can be read from the paper entitled [Culture Breakthrough \(?\)](#), dated July 12, 2008. Confirmation of this result has been postponed until it became clear that the findings could be duplicated; this is now the case.

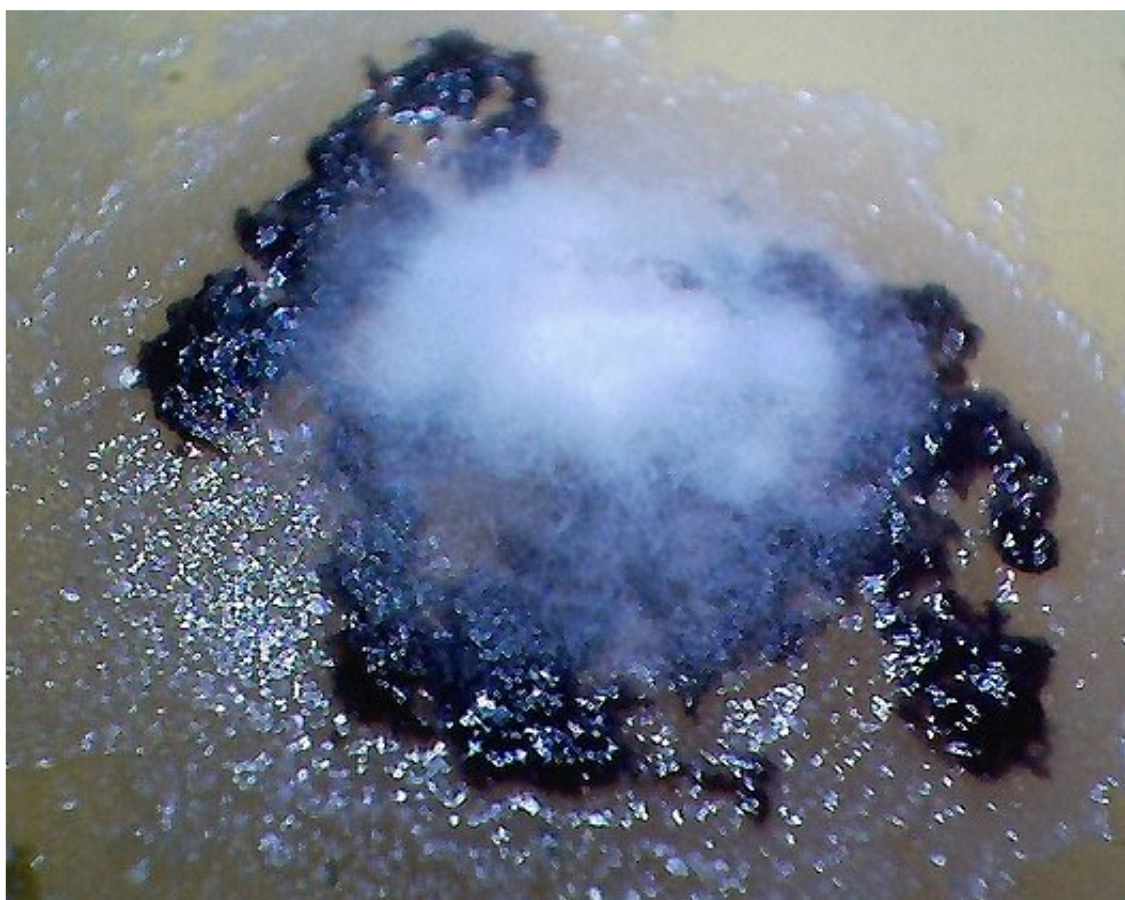This work is important in that it provides a basis for the controlled study, observation, examination and modification of a primary pathogenic form that appears to underlie the existence of the so-called "Morgellon's" condition. It is reiterated that the general population appears to be subject to the existence of the pathogen, regardless of whether certain skin "anomalies" are present or not.

It is unlikely that I will have the time or resources to conduct the studies that are called for. I will continue to do what I can when I can; proper resources are a serious issue at this point.

The public must now share in the responsibility for the progress (or the lack of it) that is dictated by this report.



A representative original dental sample on beef-bouillon agar medium. Magnification approx. 2x.



Duplicated, isolated and cultured “primary pathogenic form” growing on top of dental filament sample within bouillon agar medium.

Under high magnification, i.e., approx. 7000x, the primary pathogenic form is identical in size, shape and structure

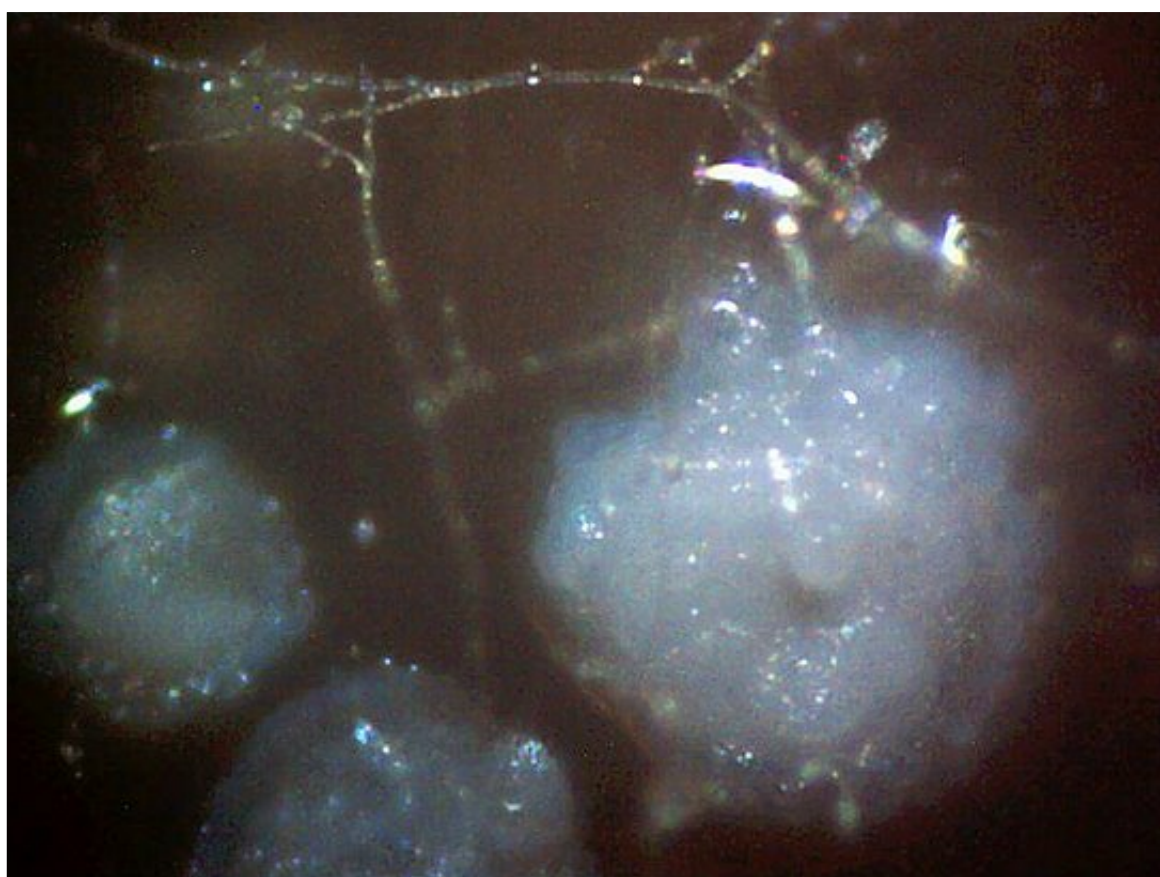
to the expelled dental samples (see additional photographs at high magnification below).

The time period for independent cultures to emerge from various dental samples has ranged from a few days to a few months. The time of development for this propagated culture is approximately one week.

This culture form is not assured to grow on each dental sample, but has occurred thus far in at least three independent cases

over varying time intervals. A broad variety of molds, fungi and bacterial have formed on most dental samples

in addition to individual instances of the filament culture.. Magnification approx. 3x.



This microphotograph demonstrates one method by which the culture appears to extend its growth.

Circular colonies are often found to establish themselves on the agar medium in a radial fashion around the primary filamentous culture. It also appears that the circular colonies are able to withstand more adverse environmental conditions, such as a decrease in moisture.

When conditions are favorable, the filaments often form an interlocking web across and between the spherical colonies.


Individual interconnecting filaments are visible within this photograph at relatively low power.

If the conditions are highly favorable to growth, (i.e., increased moisture, nutrients and a dental sample base),

the filament culture can rapidly increase as in the first photograph of this report.

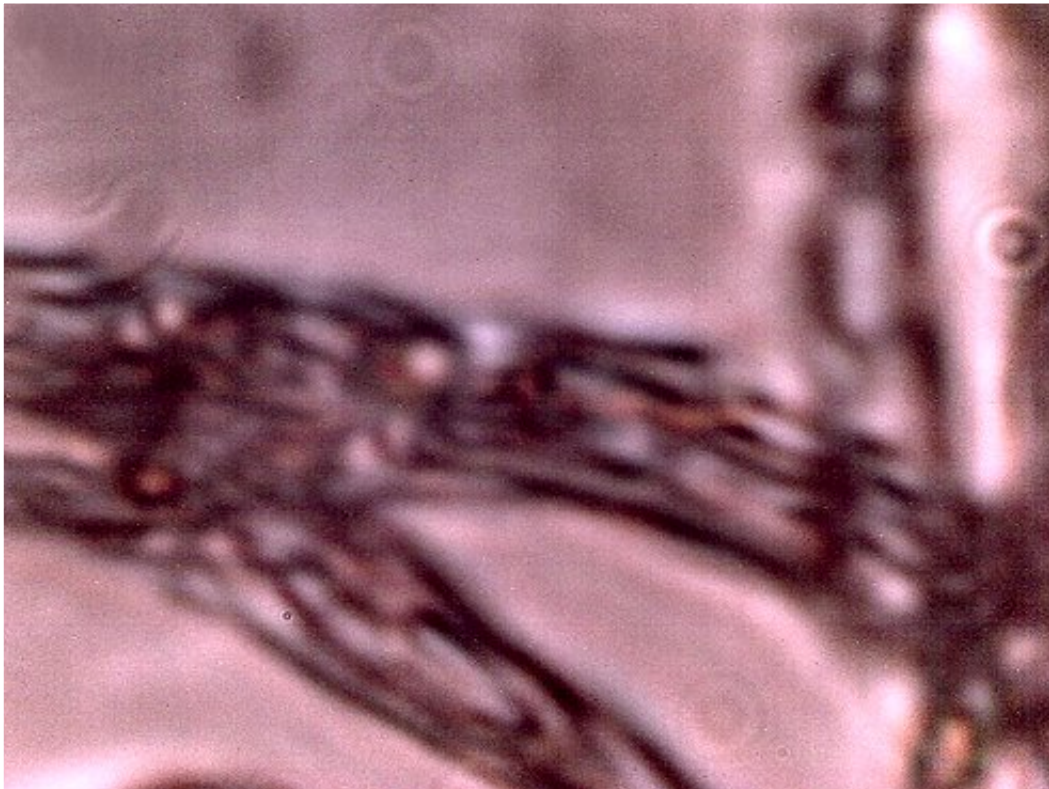Once a filament culture has developed, it appears difficult to degrade; no such degradation

has occurred to date even if environmental conditions become more adverse.
Some cultures under study are now approximately 3 months of age.
Magnification approx. 400x.

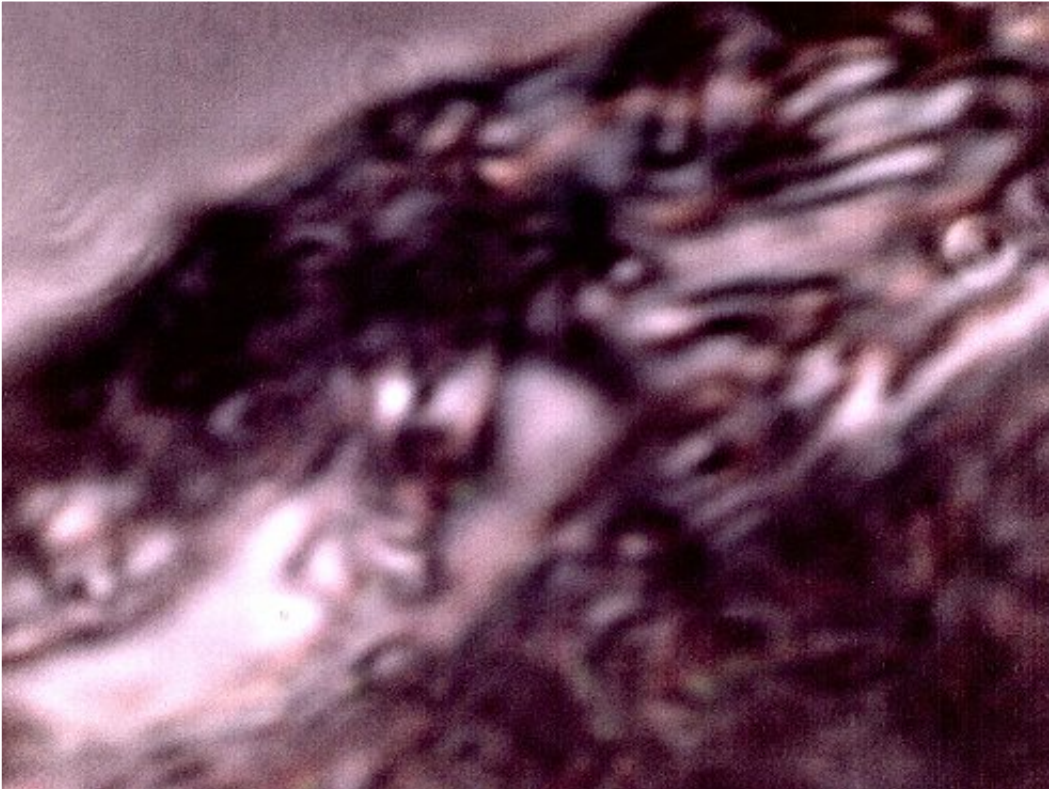

Another example of variate culture growth on the dental filament (dark regions) samples. Bacterial and fungal forms went through several stages of evolution on this culture medium. The culture has eventually culminated with the appearance and gradual growth of the primary pathogenic form(white filamentous growth) after a 2-3 month period of sustained observation. Magnification approx. 2x.

The following images are excerpted from the previous paper entitled "*Culture Breakthrough (?)*", dated July 12, 2008.



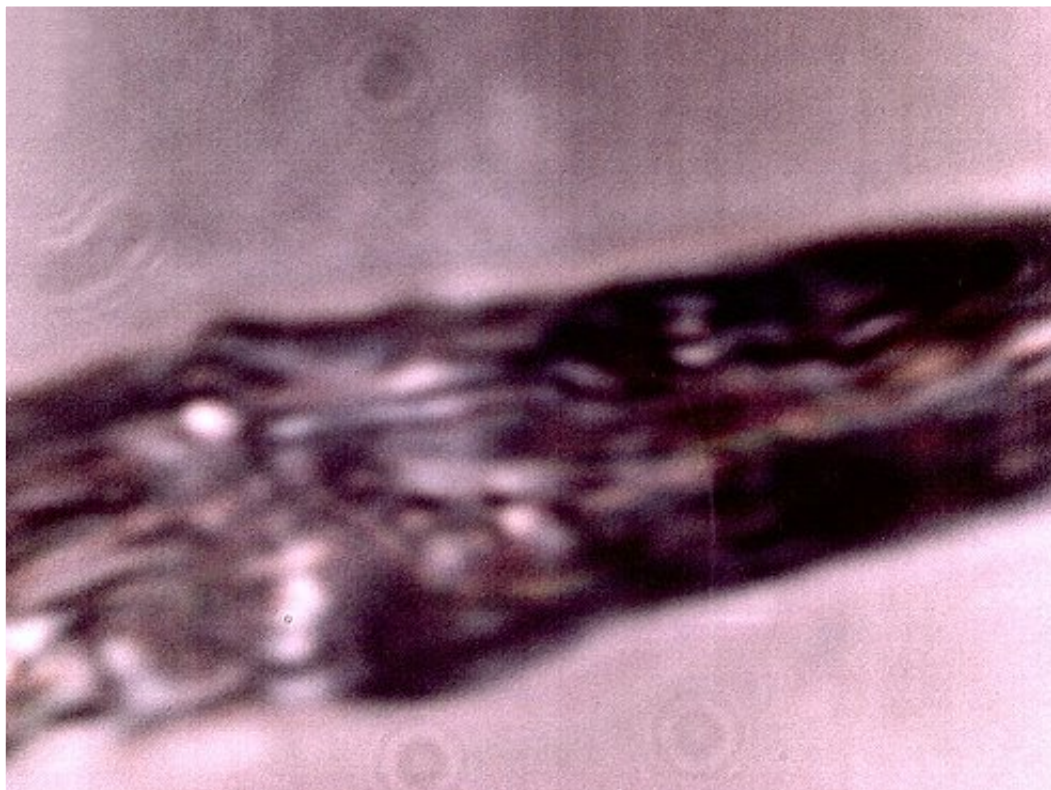
An original *DENTAL* filament sample under the modified microscope. Additional dental filament sample microphotographs are available on this site; uniformity of structure, size and form is apparent. This is to be considered as the "*primary pathogenic form*" for the purposes of this report. Magnification approx. 7000x.



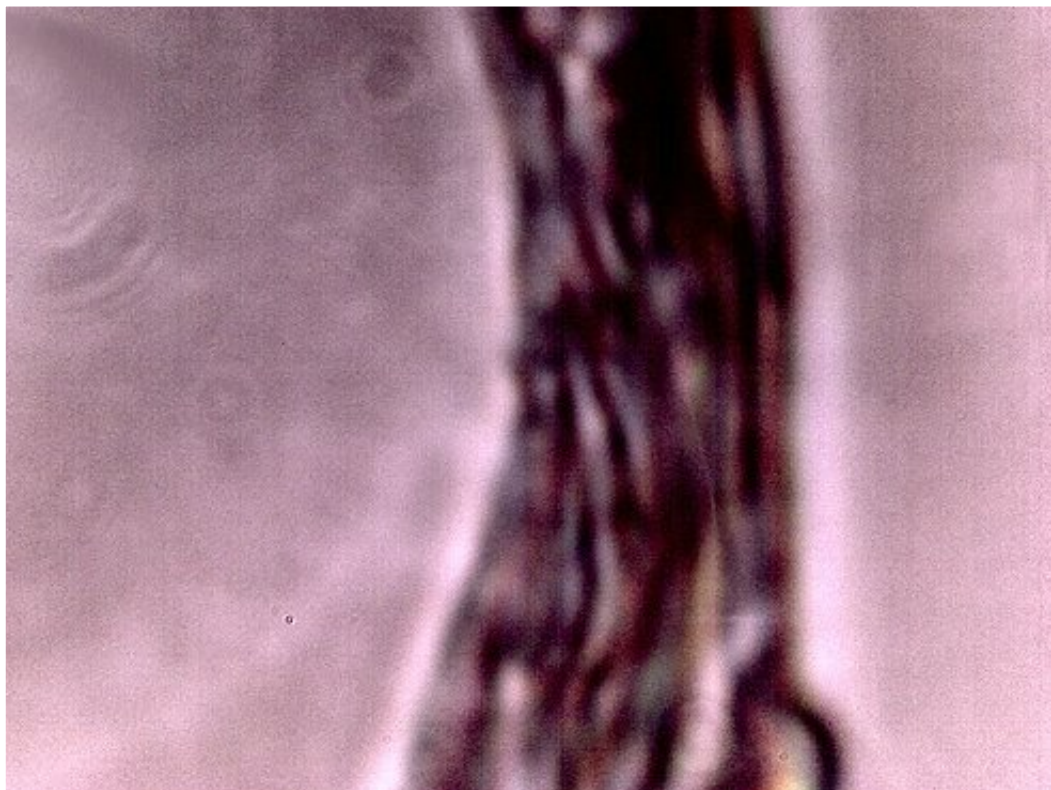
The filament from a bouillon agar culture medium growth under high magnification. It appears in all major respects(size, structure, form) to be identical to the “primary pathogenic form.”(i.e.,the dental sample).

Encasing filament,sub-micron filament network and sub-micron oblate/spherical structures are each identifiable within this microphotograph. This sample represents a *growth* on the culture medium and it is *not* the original dental sample. It develops from, and as a result of the dental filament sample and it represents a controlled development and duplication of the *primary pathogenic form*.

Magnification approx. 7000x.



Additional microphotograph of a culture medium filament sample. Similarity, if not identity, to the primary pathogenic form is apparent. This pathogenic form has been identified in ALL humans that have subjected themselves to the dental testing process. Magnification approx. 7000x.



Additional microphotograph of a culture medium filament sample.
Similarity, if not identity, to the primary pathogenic form is apparent.
Magnification approx. 7000x.

Additional information will be made available if and as time and circumstances permit.

MORGELLONS: GROWTH CAPTURED

Aug 21, 2008

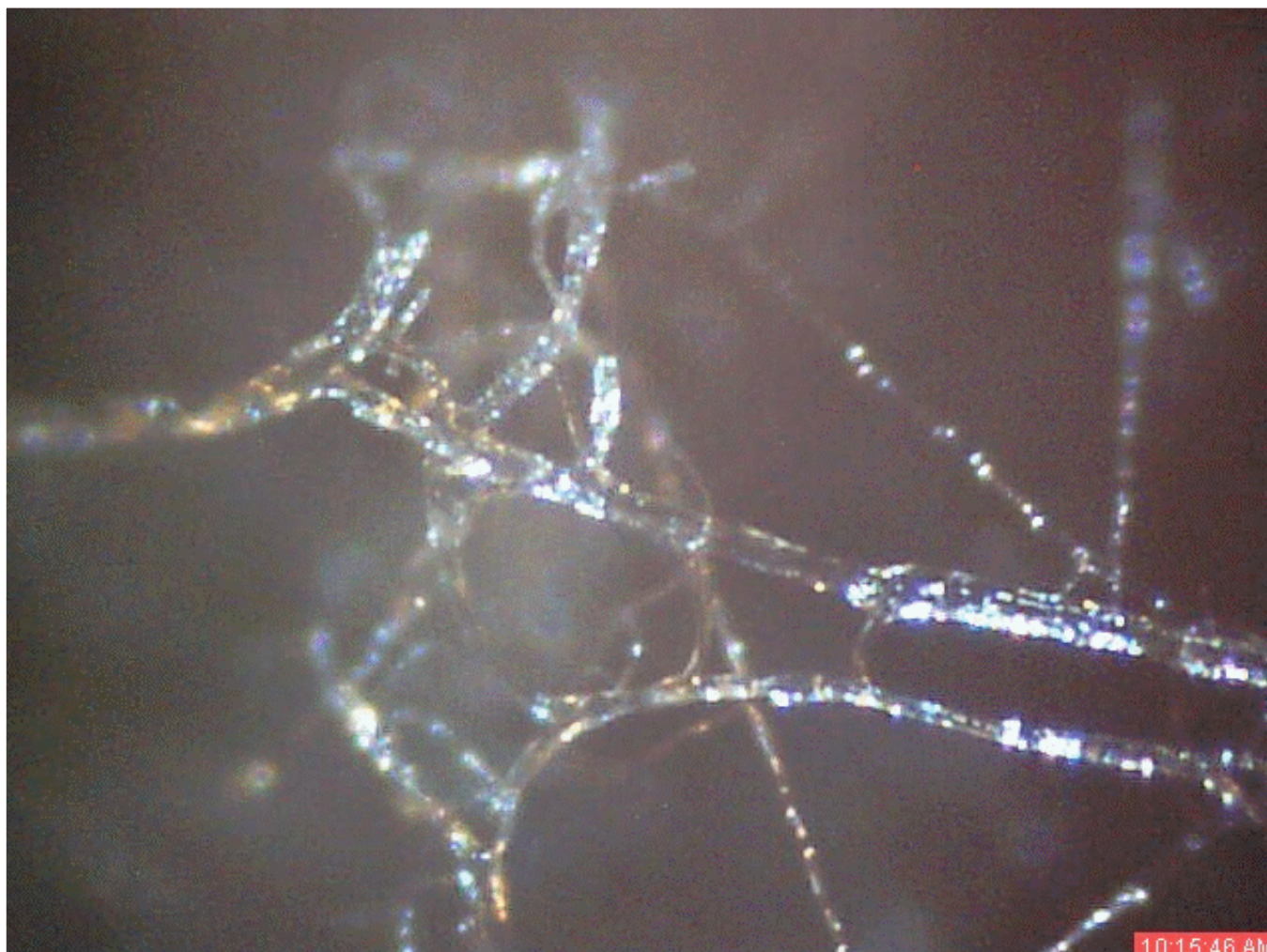
MORGELLONS: GROWTH CAPTURED**Clifford E Carnicom****Aug 21 2008**

(High speed connection required – please allow sufficient time for loading of video)

A time lapse video under the microscope has been developed which demonstrates the cultured growth pattern and behavior of a *primary pathogenic form* that is in direct association with the so-called “Morgellons” condition. The general public appears to be subject to the conditions that are shown in this report.

I am not offering any medical advice or diagnosis with the presentation of this information. I am acting solely as an independent researcher providing the results of extended observation and analysis of unusual biological conditions that are evident.

(Please refer to the recent articles on this site, [Culture Breakthrough \(?\)](#) and [Culture Work Confirmed](#) for the prerequisites to this report).



Six hour to one minute time lapse microscope video of *primary pathogenic form* under culture.

Magnification approx. 450x.

This video is of a *cultured* growth which takes place on top of a dental sample placed within an bouillon agar medium.

Please see additional images below and the recent reports on the culture work for additional information.

The time lapse video covers a period of approximately six hours and compresses the time into approximately one minute with 30 frames. The video images are time stamped in the lower right hand corner. The time interval between successive images is approximately 12 minutes. At approximately one hour into the sequence, extending filaments can be clearly seen (left center) to emerge from a primary filament. The network continues to densify from that point forward. The width of the primary filament (larger size) is approximately 12 microns in thickness, which is in accord with previous measurements for the encasing or bounding filament from direct biological samples. A reasonable estimate of the narrow filaments is on the order of sub-micron to micron range, also in accordance with previous measurements of the sub-micron internal filament network.

From the discovery shown here, it would appear that the encasing filament serves to provide feeder or extension filaments which serve to extend the growth of the pathogen. The estimated growth rate of the extension filaments on this particular culture is on the order of 50 microns per hour, or roughly the width of a thin human hair per hour.

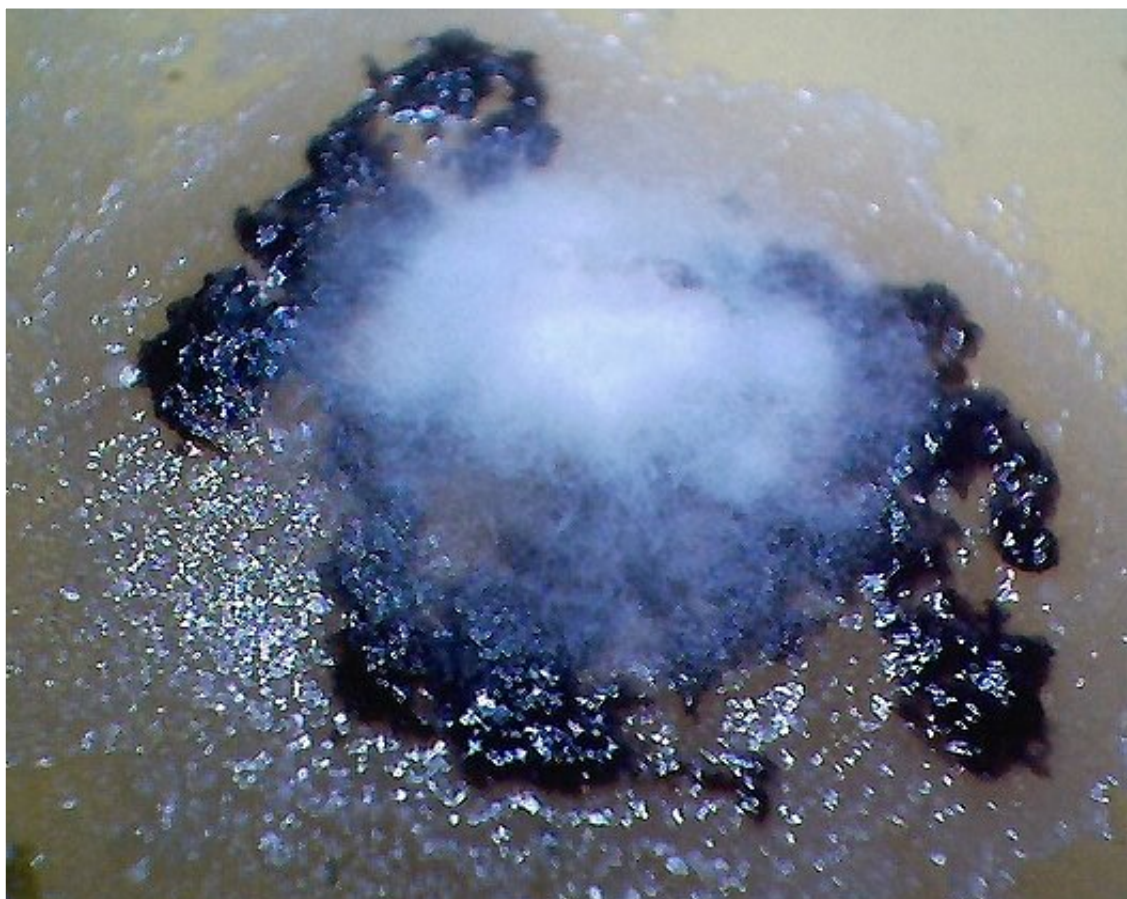
Over the course of the six hours, it can be seen that the network becomes both dense and complex.

Developing a non-toxic method of visibly impeding this growth process should be at least one priority consideration for researchers of this topic.

The lighting varies due to surrounding reflection and refraction from the growth of the surrounding network. It also varies from the densification of the immediate network state. The depth of field for the photography is quite shallow due to the magnification, and occasionally the image requires refocusing to keep the primary filament in view. The lighting is from above and oblique.

This report continues to add valuable knowledge on the morphology, characteristics and behavior of at least some of the pathogenic forms that are strongly associated with the so-called "Morgellons" condition.

The following images are excerpted from the previous paper entitled "*Culture Breakthrough (?)*", dated July 12, 2008
and *Culture Work Confirmed*, dated August 18, 2008.



Duplicated, isolated and cultured “primary pathogenic form” growing on top of dental filament sample within bouillon agar medium.

Under high magnification, i.e., approx. 7000x, the primary pathogenic form is identical in size, shape and structure

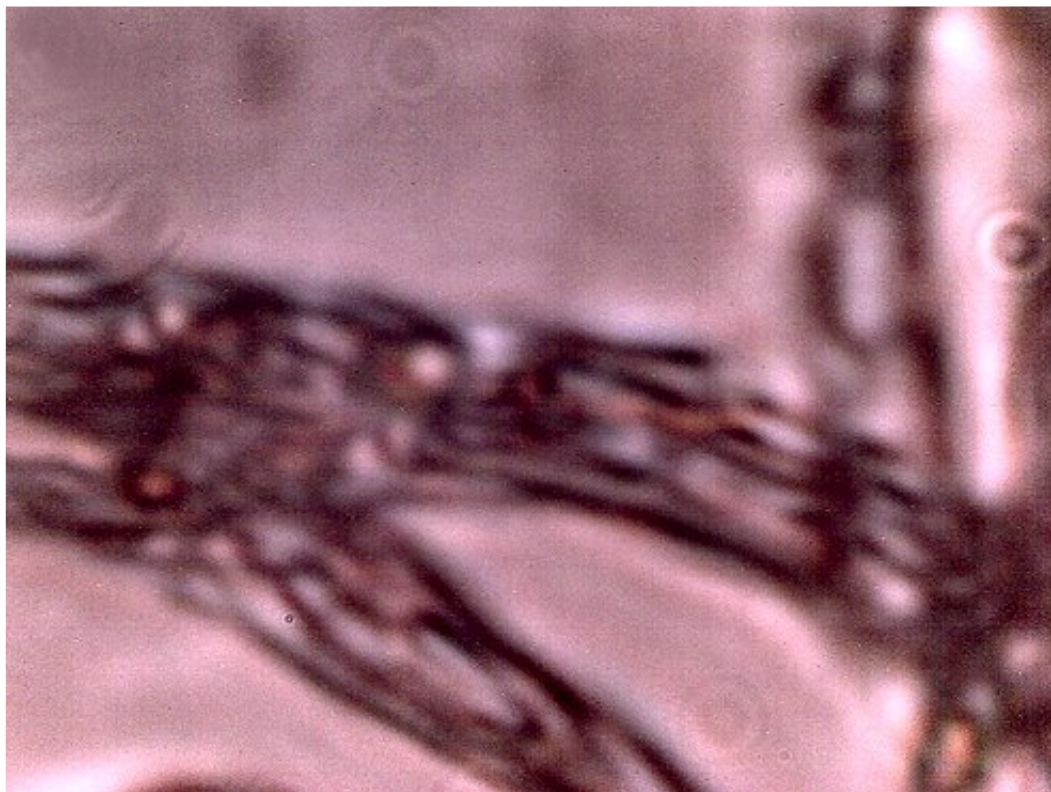to the expelled dental samples (see additional photographs at high magnification below).

The time period for independent cultures to emerge from various dental samples has ranged from a few days to a few months. The time of development for this propagated culture is approximately one week.

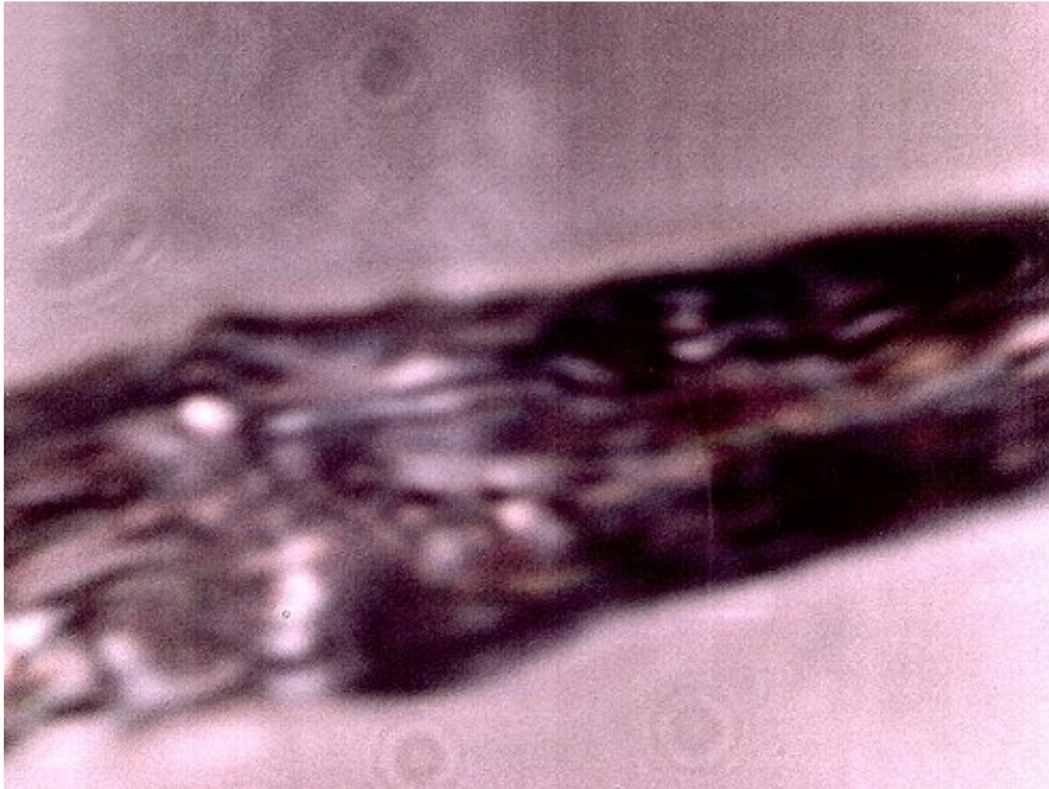
This culture form is not assured to grow on each dental sample, but has occurred thus far in at least three independent cases

over varying time intervals. A broad variety of molds, fungi and bacterial have formed on most dental samples

in addition to individual instances of the filament culture.. Magnification approx. 3x.



An original *DENTAL* filament sample under the modified microscope. Additional dental filament sample microphotographs are available on this site; uniformity of structure, size and form is apparent. This is to be considered as the "*primary pathogenic form*" for the purposes of this report. Magnification approx. 7000x.



The filament from a bouillon agar culture medium growth under high magnification. It appears in all major respects(size, structure, form) to be identical to the “primary pathogenic form.”(i.e.,the dental sample).

Encasing filament,sub-micron filament network and sub-micron oblate/spherical structures are each identifiable within this microphotograph. This sample represents a *growth* on the culture medium and it is *not* the original dental sample. It develops from, and as a result of the dental filament sample and it represents a controlled development and duplication of the *primary pathogenic form*.

Magnification approx. 7000x.